



Efficacy of Jalaukawacharan on Dushtavran: A Case Study

Dr. Rushikesh Jagannath Andhare. M.S-Shalya¹,
Dr. Miteshkumar Dilipkumar Gujrathi. M.S-Shalya²

¹ Assistant Professor, Department of Shalya tantra, Gramin Ayurved Mahavidyalaya Patur, Dist Akola, Maharashtra, India

² Assistant Professor, Department of Shalya tantra, MUP's Ayurved College, Hospital and Research Center, Degaon, Risod Dt Washim, Maharashtra, India

Abstract: Complications of chronic venous insufficiency are growing more common. Adults with chronic ulcers of the lower legs are rather prevalent; it affects 1% of the adult population and 3.6 percent of those over the age of 60. When a venous valve is broken, it stops blood from flowing backwards, causing pressure in the veins, which leads to hypertension and venous stasis. These are most common along the medial distal leg, which can be quite painful and bleed, resulting in Varicose Ulcers (Stasis ulcers). Though a lot of treatment ideas have been described and practised in allied sciences, treating a varicose ulcer is a separate task for the physician. This ailment is known as Dushtavrana in Ayurveda. It can be treated with Raktamokshana, or Jalaukawacharan, a specialized Shodhan therapy (Leech therapy). During the follow-up phase, it was discovered that the outcomes obtained are effective and stable.

Keywords: varicose ulcer, Dushta vrana, Leech therapy, Raktamokshan, Jalaukawacharan.

Introduction

Man has been plagued by a variety of life-threatening diseases and injuries since the dawn of time. These injuries are sometimes overlooked by men, resulting in complications later on. Dushtavrana refers to a wound that does not heal or heals very slowly despite greatest attempts. Varicose Ulcers occur when vrana (wound) is caused by varicosity of veins. It is caused by venous valves that do not function properly, especially in the lower limbs. Damaged venous valves prevent blood from flowing backwards, causing pressure in veins and tension, which leads to venous ulcers. Diabetes, tuberculosis, and diseases such as protein deficiency and poor blood supply all slow the healing of ulcer.

In Venous ulcer, there is insufficient blood supply to the ulcerative part which causes delay in the healing process. The longer the duration of the venous ulcer, the more is the damage to skin and underneath tis-sues. If it gets more worsen then requires Skin grafting. With review and reference of ancient approach to vrana treatment, With a review and comparison of ancient approaches to vrana treatment, it is clear that the Ayurvedic approach to vrana treatment is superior. Acharya Sushruta has carefully discussed Shashti upkrama (sixty techniques), one of which is Rak-tamokshan (Bloodletting), to obtain good approximation, early healing, and an acceptable scar without many complications.

AIMS AND OBJECTIVES

The study's major goal is to see how effective Jalaukavacharan (Leech therapy) is for treating Dushtavrana (Non-healing ulcer).

CASE STUDY

A 48 years old male patient presented to the shlyatantra OPD with varicose ulcers, extensive discoloration, and tortuous veins at left ankle joint. He was also experiencing acute local pain and a burning sensation in the same location. He was diagnosed with Dushtavrana (non-healing varicose ulcers) after experiencing recurrent varicose ulcer at the Ankle Joint for the past 6 years.

Patient had a 10-year tobacco chewing addiction, yet he was able to break free after only 1 years. From the last 15 years, he had become accustomed to standing for lengthy periods of time in his routine work, i.e. 8-10 hours every day. There was no previous history of any chronic or significant ailment, such as diabetes or hypertension.

He had chosen Allopathic treatment instead of Ayurvedic treatment and then undergone EVLT (Endovenous Laser Therapy) but had no alleviation. He received Allopathic treatment for nearly 4 years before coming to our Ayurvedic facility for treatment. We have decided to treat this instance with Jalaukavacharana and some Ayurvedic medicine after thoroughly examining her and inspecting the status of her wound. We performed 5 Jalaukavacharan sittings, which provided total and great alleviation to the patient, and the wound was entirely cured.

GENERAL EXAMINATION

A reddish big ulcer with sloping borders was discovered, as well as minor serous leakage around the medial region of the left leg's ankle joint. The ulcer was 3 cms long, 4 cms wide, and 1 cms deep. Swelling and blackish discoloration around the left ankle joint and feet, as well as tenderness surrounding the ulcer, plagued the patient.

Varicosity on the left lower limb's calf region tested positive for the Trendelenburg test, and pedal pulse was present, indicating varicose ulcer symptoms.

ASSESSMENT CRITERIA

Ativivrutavrana (spreading nature), Utsanna (elevated margin), Raktavarna (reddish), Srava (Secretion present), Daha (burning feeling), and Shopha are the symptoms present at the location of Vrana (wound) (Swelling). Dushtavrana was diagnosed based on this (pitta predominant vrana). The patient's informed consent was obtained for the documentation and dissemination of the case history.

MATERIAL USED FOR JALAUKA-VACHARAN

Haridra powder (Turmeric Powder)

Jalauka

Gauze pieces (sterilised)

dressing pad

cotton

gloves

a disposable syringe

kidney tray

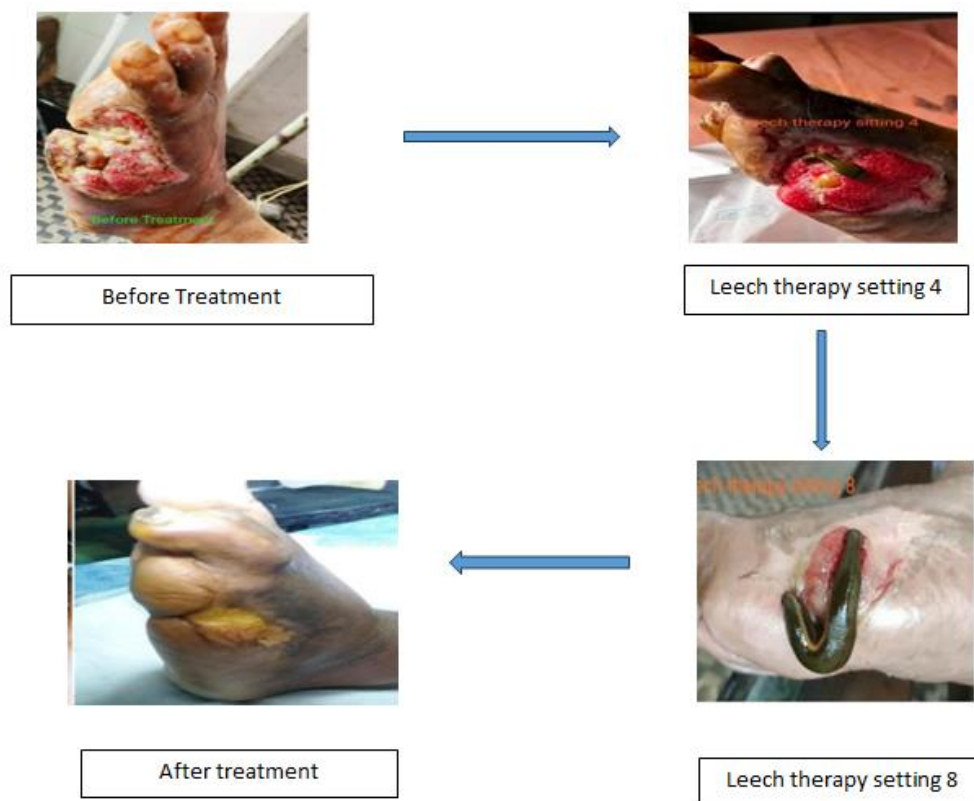
Water(normal saline)

Crepe bandage

METHOD

The following treatment plan was followed:

- 1) On an outpatient basis, the patient had 5 sittings of Ja-laukavacharana (once a week). Jalaukavacharana was performed according to Acharya Sushruta's instructions.
- 2) As determined by measurement, pain was quantified on a visual analogue scale (VAS) as well as the granulation tissue



DISCUSSION

The patient who was treated with Jalauka had a superior outcome, with a higher proportion of exudates, smell, granulation, and wound circumference reduction. Jalaukavacharan has a broad therapeutic effect in lowering srava/exudates by calming the vitiated doshas, as well as Pitta and Raktadosha, which are the gandha's causal components. The granulation tis-sue in the wound bed had been encouraged by the leech.

CONCLUSION

It is usually preferable to follow the notion of Ayurveda treatment for illnesses like chronic non-healing ulcers where the pathogenesis is so far advanced and not responding to Allopathic treatment at all.

The Ayurvedic Classics treatment procedure for DushtaVrana (Non-healing Wound) specifies that it must be treated with Rak-tamokshana (Bloodletting). Choose the right sort of Raktamokshana based on the Dosh predominance at the Vrana (wound) site. Jalaukavacharana is particularly efficient in the treatment of chronic non-healing ulcers, according to this Case Report. It is always recommended in such circumstances because it is also cost effective and has less difficulties.

REFERENCES

1. Sushruta Samhita of SushrutaChikitsasthana 1/8 with Ayurveda TatvaSandipikahindi commentary by KavirajaAmbika Dutta Shastri, Chaukhambha Sanskrit Sansthan Varanasi, Part 1-2,9th edition 1995.
2. Sushruta Samhita of SushrutaChikitsasthana 1/8 atwith Ayurveda Tatva San-dipikahindi commentary by Kaviraja Am-bika Dutta Shastri, Chaukhambha Sanskrit Sansthan Varanasi, Part 1-2,9th edition 1995.
3. Sushruta Samhita of Sushruta Sutra sthana 21/40, Chikitsasthana 1/16 with Ayurveda TatvaSandipikahindi commentary by Ka-virajaAmbika Dutta Shastri, Chaukhambha Sanskrit Sansthan Varanasi, Part 1-2,9th edition 1995.
4. Sushruta Samhita of Sushruta sutra sthana chapter 13 with Ayurveda TatvaSandipikahindi commentary by KavirajaAmbika Dutta Shastri, Chaukhambha Sanskrit Sansthan Varanasi, Part 1-2,9th edition 1995.