



CLINICAL FEATURES OF THE COURSE OF CHICKENPOX AT THE PRESENT STAGE

Arashova Gulnora Amirqulovna

Bukhara State Medical Institute named after Abu Ali ibn Sino

Abstract: From January 2022 to December 2022, 201 patients aged 2 months to 52 years were treated at the Bukhara Regional Infectious Diseases Hospital, including 126 (63%) children aged 2 months to 17 years and 75 (37%) adults aged 18 to 52 years. patients, most of whom were men. Epidemiological and anamnestic anamnesis, clinical course of the disease, clinical-laboratory results were analyzed in all patients, and characteristics of the clinical course in children and older patients with chicken pox were studied.

Key words: chickenpox, rash, vesicle, pustulation, fever, lymphadenopathy.

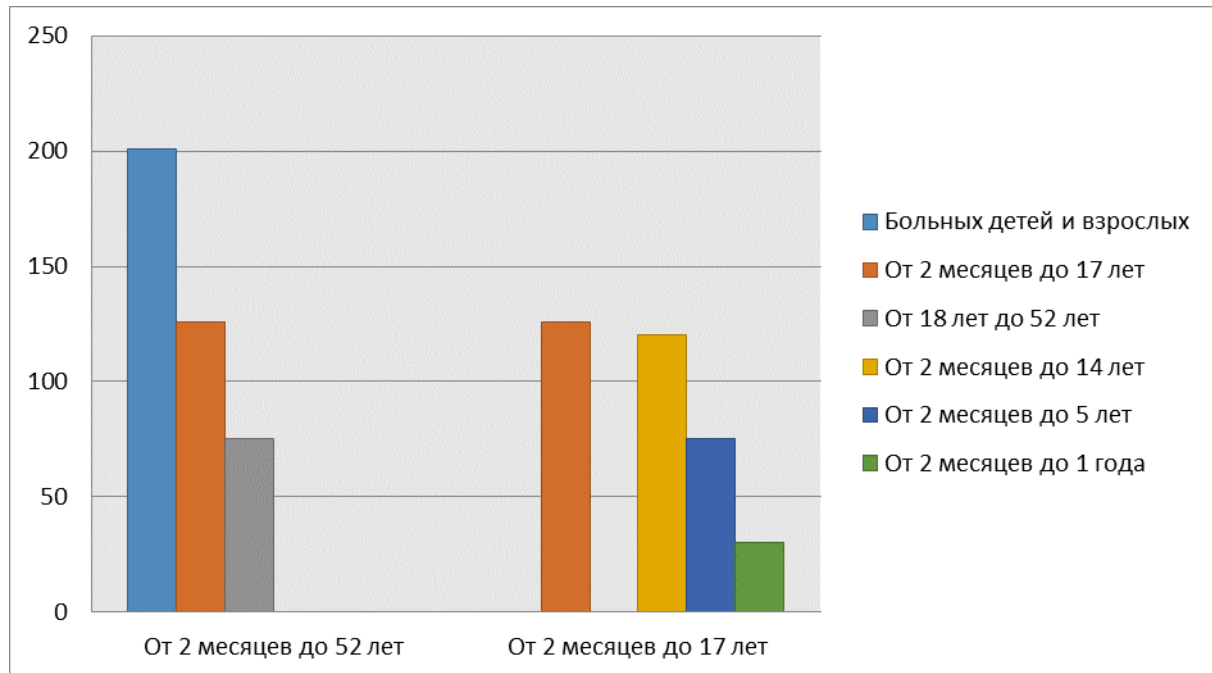
Introduction

Chickenpox is one of the most widespread highly contagious infections, the susceptibility to which reaches 95-100% [1]. Against the background of a decrease in the incidence of “controlled” infections in the structure of infectious pathology, the importance of chickenpox increases. The urgency of the problem is determined by the high incidence of chickenpox, the ubiquitous spread of the pathogen, the increase in the share in the general infectious pathology, significant economic damage, and the ineffectiveness of preventive measures implemented in practice (isolation of patients, quarantine). Chickenpox is an acute viral disease predominantly of childhood, however, given its wide distribution and high contagiousness, it often occurs in the adult population, when the disease is more severe and the percentage of complications is higher. [1,2]. The current epidemic process of varicella is characterized by a tendency for the infection to “grow up”, especially among the urban population. Every year, 5 to 6% of cases are adults. The number of sick adolescents aged 15 to 17 years is 3-5% [2,3].

Over the past 5 years, the incidence rate among the adult population has increased 5 times. The greatest risk of an unfavorable course of chickenpox is in persons with an immunodeficiency state of any genesis, affecting the cellular link of immunity.

The goal is to study the clinical features of chickenpox in patients hospitalized in the department of the Bukhara Infectious Diseases Hospital in 2022 year, and to conduct a comparative analysis of the clinical course of the disease in children and patients over 18 years of age.

Materials and Methods . Under observation were 201 sick children and adults aged from 2 months to 52 years with a diagnosis of chicken pox, who were admitted to the department of the Bukhara Infectious Diseases Hospital from January 2022 to December 2022. Among them, 126 (63%) were aged from 2 months to 17 years, 120 from 2 months to 14 years, from 2 months to 5 years - 75, from 2 months to 1 year - 30, from 18 years to 52 years was 75 (37%) were dominated by men, predominantly aged 18 to 52 years.



The diagnosis of chicken pox was established on the basis of complaints, medical history and objective data. In all patients, the data of the epidemiological anamnesis and the anamnesis of the development of the disease, the clinical course of the disease were analyzed, a clinical and laboratory examination was carried out, which made it possible to identify the clinical features of this disease at the present stage.

Results and Discussion . As is known, for various infectious diseases, an epidemiological history is important for making a diagnosis, which allows you to identify the source of the infection and timely start anti-epidemic measures both in organized groups and closed institutions, and in family foci. From the epidemiological history, it was found that 175 patients (87%) had contact with patients with chickenpox, and the remaining 14 patients (7%) were hospitalized not only for clinical, but also for epidemiological indications: persons living in hostels in 12 cases (6%) did not have direct contact with patients with chickenpox.

Observations showed that the clinical symptoms of chickenpox in adults did not differ from those in children, but the disease was much more severe. Thus, in 82.8% of patients the course of the disease was regarded as moderate, in 9.0% as severe, and only 8.2% as mild. The severity of the disease was determined by the severity of symptoms of intoxication, temperature reaction and the nature of the rash. In typical cases, the disease developed acutely (82%) or subacutely (18%).

An analysis of the clinical course of the disease in children showed that in (88%) children the disease developed acutely from the prodromal period (1-2 days), during which malaise, weakness, fever from subfebrile to high (39°C) figures were noted, capriciousness, tearfulness, poor appetite. For outpatient medical care, 94% of patients applied during the first day (1-2 days) from the onset of the disease to the appearance of the first elements of the rash.

According to the literature, chickenpox in adults is characterized by a longer prodromal period, if in children it is 24-72 hours, then in adults it can reach 7-10 days, thereby making timely diagnosis difficult and increasing the risk of infection of contact persons. The onset of the disease in adults 46 (60%) patients was acute, in 30 patients (40%) - subacute onset with a prodromal period that lasted from 1 to 5 days.

The prodromal period in the patients we observed lasted from 1.5 to 5 days, during which there was an increase in body temperature from subfebrile to high numbers ($39-40^{\circ}\text{C}$), malaise, headache, general weakness, decreased performance, lethargy, drowsiness in all 62 adult patients. In most cases, an increase in body temperature was noted on the first day of illness - in 44 (71%) patients, however, in 11 (18%) patients this symptom appeared on the second day of illness, in 4 (6%) on the 3rd-4th day of illness, and in 3 (5%) it was short-term within one day (rising temperatures up to $37.2-37.5^{\circ}\text{C}$). Hospitalization of patients was carried out during the period of rashes on the 2-4th day of illness in 60 (97%) cases. However, hospitalization was also noted in the later stages of the disease - on the 5-6th day in 3% (2 people) of cases.

The period of rash began mainly with the appearance of one or two large maculopapular elements, very quickly turning into vesicles or pustules. Over the next day, the papular-vesicular rash increased rapidly and spread with sprinkling to the face, scalp (44.7%), behind the ear (26.8%) or simultaneously on the scalp and behind the ear (28, 5%). In the next 1-4 days, the rash began to spread to the face, neck, trunk, upper and lower extremities. At the same time, in 54 (87%) patients on the lower extremities, the rash was scanty. Sleeping continued in 53 (85%) patients for 3-4 days, accompanied by skin itching. Within a few hours, the rash became vesicular, then gradually began to dry out with the formation of crusts, which completely disappeared on the 7-12th day. In 36 (58%) patients, the rash was extremely profuse, almost completely covering the face and trunk. During the height of the disease in children, rashes were plentiful, especially on the trunk and extremities, accompanied by skin itching in 38% of patients; in some patients (23%), enanthema was found on the mucous membranes of the oral cavity; The period of rashes lasted an average of 3-4 days. In 42% of cases, lymphadenopathy was diagnosed with an increase in cervical, axillary and inguinal lymph nodes. A distinctive feature of the rash in adults was rapid and profuse pustulization, which was observed in almost half of 26 (42%) patients. Pustulization was accompanied by a significant ($39-40^{\circ}\text{C}$) rise in temperature, and pyoderma was so pronounced that it required additional antibiotic therapy, and in 7 cases (11%) the disease had a severe severity associated with the severity of

pyoderma and existing concomitant pathology. It was characterized by high temperature (39-40)°C from the first days of illness, severe intoxication, manifested by headache, dizziness, severe weakness, sleep disturbance, nausea, repeated vomiting, lack of appetite, as well as profuse rash, with severe itching, pustulization and symptoms of comorbidities.

In all patients, at the height of the disease, catarrhal phenomena were observed, such as a runny nose, dry cough, and lacrimation. In 36 patients (58%), rashes were observed on the conjunctiva, which was accompanied by the development of scleritis and conjunctivitis within 3-5 days of the rash period. Exanthema in 94% of cases was accompanied by enanthema on the oral mucosa, mainly in the region of the palatine arches and soft palate. Thus, the oropharyngeal mucosa was brightly hyperemic in 23 (24%) patients, moderate hyperemia was observed in 18 (27%), and weak in 31 (47%), while all of them had graininess of the tonsils, arches and posterior pharyngeal wall. The enanthema first looked like bright pink papules, and then turned into vesicles, which quickly opened with the formation of ulcers covered with a white-yellow coating. 8% of patients developed stomatitis, which caused severe pain when eating.

It should also be noted that the period of rashes was accompanied by intoxication and asthenovegetative syndromes: severe headache in 57 (92%) patients, malaise and weakness in all 62 adult (100%) patients; 32 (52%) patients had pain in the lumbar region, 5 (8%) patients had nausea, vomiting, abdominal pain.

High fever was recorded in 47 (76%) patients - an increase in body temperature to (38.8-39.9) ° C, in 15 (24%) patients subfebrile temperature was noted. The feverish period in uncomplicated cases lasted 6-7 days, with the development of complications it lengthened to 9-10 days. Usually the temperature returned to normal with the end of the period of pouring.

In 92% of cases, the disease was accompanied by lymphadenopathy with a predominant increase in cervical and behind-the-ear lymph nodes. With pustulization, lymphadenopathy was expressed especially sharply. Enlarged lymph nodes were determined visually when the head was tilted.

Conclusions .

Thus, in the structure of hospitalized patients with a verified diagnosis of chickenpox, children aged 3 to 14 years significantly predominated. (120) and adults from 18 to 52 years old was 75 , more often males were sick.

Chicken pox, both in adults and in children, it proceeded typically, with severe cyclicality, the presence of leading symptoms of the disease and was characterized in most cases by more severe complications, unlike children, in adults, it was manifested by a long prodromal period, a pronounced general infectious syndrome, lymphadenopathy , abundant polymorphic rash with itching, with a duration of rashes from 5 to 8 days and early pustulation, enanthema with scleritis and conjunctivitis was noted. The uneven course of the disease was accompanied by the

development of complications in persons with a premorbid background, in elderly people (pneumonia, encephalitis, etc.).

Literature:

1. Sergeeva I.V., Lipnyagova S.V., Beckert A.I., Levitsky S.V., Borisov A.G. Modern features of the course of chickenpox//Modern problems of science and education.- 2015.–No. 5 .
2. Sitnik, T.N. Chicken pox: “grown-up” infection / T.N. Sitnik, L.V. Steinke, N. V. Gabbasova // Epidemiology and vaccinal prevention: journal. - 2018. - No. 17 (5). - 55–58s.
3. Chickenpox in children in modern conditions (epidemiology, clinic, diagnosis, therapy, prevention): a medical guide for doctors / ed. Yu.V. Lobzin. SPb., 2011. 80 p.
4. Martynova G.P., Kutishcheva I.A., Evreimova S.V., Karasev A.V. et al. Clinical and epidemiological features of chickenpox at the present stage // Infectious. illness. 2012. V. 10, No. 4. S. 18–22.
5. Vikulov G.Kh. Human herpesvirus infections in the new millennium: classification, epidemiology and medical and social significance // Epidemiology and infectious diseases. 2014. No. 3. P. 35–40.
6. Zheleznikova G.F., Lobzin Yu.V., Skripchenko N.V., Ivanova G.P. Clinical significance of serum levels of cytokines in chicken pox in children // Infection and Immunity. 2015. V. 5, No. 1. S. 79–84.
7. Infectious diseases: national guidelines / edited by N.D. Yushchuk, Yu.Ya. Vengerov. M .: GEOTAR - Media , 2009. 1040 p .
8. Nasullaevna, H. N., & Vohidovna, O. D. (2021). The efficiency of glossalgia and stomatalgia complex treatment. *Биология и интегративная медицина*, (6 (53)), 374-379.
9. Arashova G.A. On the issue of the course of chickenpox in adults. 2019 Journal of Problems of Biology and Medicine, Vol.1, No. 4.2, Pages 7-9
10. Arashova G. A. Measles in adults. 2022. Journal New Day in Medicine No. 2(40), Pages 556-559
11. Arashova GA Observation of the Immuno-Pathogenetic State of Measles in Adults. International journal of health systems and medical sciences.Vol.1 NO. 5 (2022)
12. Arashova GA, Ismoilov II Methods of early detection of rejection in a kidney transplant from a relative donor. Academician Globe: Inderscience Research 2021/5/21 T - 2 No. 5. - P. 293-295
13. Arashova G.A., Gulamov M. Kh. Morphological and Functional Aspects of the Lymphatic System and its Current Problems. International Journal of Innovative Analyzes and Emerging Technology. 2021/10/5 T -1, No. 5.-P. _ 149–152

14. Arashova G.A. Clinical and epidemiological features of measles in adults. 2022. Journal of Infection, Immunity and Pharmacology Vol.1, No. 2, Special Issue. Part 1. Pages 12-17
15. Varicella and herpes zoster vaccines : Who position paper, June 2014: [[eng .](#)] // Weekly epidemiological record. - 2014. - No. 25 (20 June). -268-289p. — Memorandum WHO By wind smallpox .
16. Артыкова М. А., Набиева Н. А. Клинико-анамнестические факторы риска развития симптоматической эпилепсии при детском церебральном параличе //журнал неврологии и нейрохирургических исследований. – 2021. – №. SPECIAL 1.
17. Artikova M. A., Djurayeva D. N. Clinical and anamnestic risk factors for the development of symptomatic epilepsy in infantile cerebral palsy //Web of Scientist: International Scientific Research Journal. – 2021. – Т. 2. – №. 10. – С. 29-34.
18. Nasullaevna H. N. Characteristic features of free-radical processes and antioxidant protection in the oral cavity during chronic recurrent aphthous stomatitis //European science review. – 2018. – №. 9-10-2. – С. 191-193.