



Characteristics of the Heart against the Background of Pneumosclerosis of the Lungs after Drug Correction

Rajabov N. G¹

¹ Bukhara State Medical Institute

Abstract: As a result of pneumosclerosis, severe heart failure occurs in the body. The development of this heart failure is a long-term fatigue of the myocardium due to overwork, which is explained by the outflow of blood from the heart into the large vessels (overwork fatigue) or as a result of an excessive increase in blood flow to the heart. The purpose of the work was to fill in the results and data after the pharmacological correction of the morphological changes in the heart of white rats with pneumosclerosis in experimental conditions.

Keywords: pneumosclerosis, morphometry, cardiomyocyte

Relevance Since ancient times, pomegranate has been known not only as a food product, but also as a medicinal plant in the field of medicine. A few centuries ago, Abu Ali ibn Sina, who was known throughout the eastern countries under the nicknames of Hippocrates and Avicenna, wrote about its healing properties. Pomegranate seeds contain up to 20% oil, the main part (40%) is olein, (16%) unsaturated fatty acids such as palmitic, stearic, as well as triglycerides, steroid, lignin and A, V, S It consists of microelements such as E, group vitamins, iron, potassium, calcium, magnesium, copper, nickel, phosphorus, and zinc. Pomegranate oil has many healing properties, especially the phytosterol contained in it reduces the inflammatory process by stimulating collagen synthesis, and linoleic acid has a positive effect on the cardiovascular system. Therefore, we used pomegranate seed oil in our experiment. White rats suffering from chronic pneumosclerosis were injected with 1 drop of pomegranate seed oil through the digestive system every day for 3 months, and the results were analyzed.

Material and methods. In our study, after 90 days 4; 5; 6; 7; 8; An experimental model of pneumosclerosis was created in 180 one-month-old purebred rats, and positive changes in the heart after treatment with pomegranate seed oil for 3 months were analyzed.

Results and conclusions. According to our results, after the treatment of 4, 5, 6, 7, 8-month-old white rats with pomegranate seed oil, the following data were obtained:

Macroscopically, the heart of 4-month-old rats of experimental group 3 was asymmetrically located in the anterior thoracic cavity, and most of it was located on the left side of the midline. A large part of the front surface of the heart together with the pericardial layer is covered by the lung, and its front edges together with the respective parts of both pleuras pass through the front side of the heart and separate it from the front chest wall. Macroscopically, with the exception of a slight increase in heart organometric parameters, no other visible pathological changes were detected.

3 - research group, the total total body mass of the heart of 4-month-old purebred rats is from 138 g to 151.98 g, the average is 143.3 ± 1.2 g, the absolute heart mass is from 610 mg to 656.5 mg, on

average 638.01 ± 0.32 mg, the relative mass of the heart per 1 g of body mass is from 2.28 mg to 4.33 mg, on average 3.35 ± 0.14 mg, the length of the heart is from 0.67 cm to 1 to .5, the average was 1.11 ± 0.06 cm.

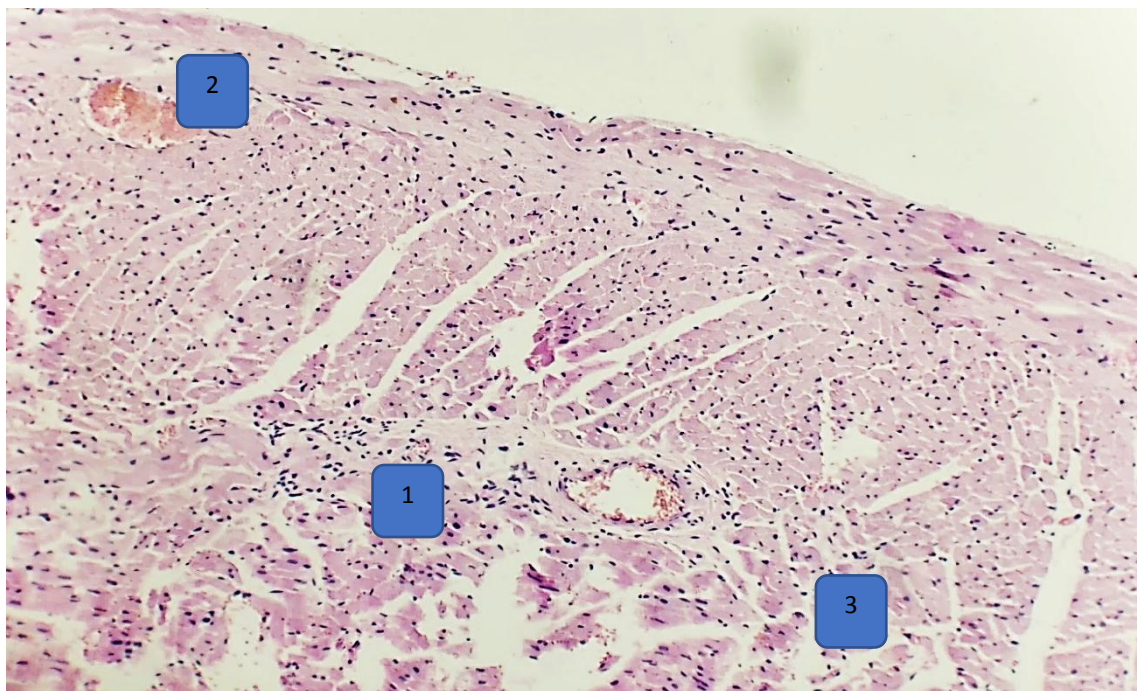
The diameter of right atrium cardiomyocytes is from $7.98 \mu\text{m}$ to $8.78 \mu\text{m}$, with an average of $8.46 \pm 0.06 \mu\text{m}$, and the diameter of left atrium cardiomyocytes is from $8.92 \mu\text{m}$ to $10.89 \mu\text{m}$, on average $9.67 \pm 0.15 \mu\text{m}$, right ventricular cardiomyocytes diameter from $7.6 \mu\text{m}$ to $10.71 \mu\text{m}$, on average $9.19 \pm 0.21 \mu\text{m}$, left ventricular cardiomyocytes diameter $11.41 \mu\text{m}$ to $13.54 \mu\text{m}$, the average is $12.85 \pm 0.15 \mu\text{m}$.

As a result of macroscopic, histological, and histomorphometric studies, it was found that there are a number of morphological changes in the hearts of 4-month-old white rats after treatment for 3 months against the background of chronic pneumosclerosis in experimental group 3 of the study.

In visual assessment, macroscopically, after 3 months of treatment against the background of chronic pneumosclerosis, the organometric parameters of the rat heart at 4 months did not show significant changes from the values of the control group.

The results of the histological examination showed that after 3 months of treatment against the background of chronic pneumosclerosis, several obvious changes were detected in the structure of the heart of 4-month-old rats.

In the interstitial tissue of the heart myocardium consisting of cellular elements, there are focal and diffuse infiltrates consisting mainly of neutrophils and eosinophilic granulocytes, fullness of venous blood vessels and dimming of their cavity due to erythrocyte mass, dystrophic muscle fibers changes were found. In addition, histologically, pathomorphological signs such as focal and diffuse hemorrhage zones were not detected.



Picture 1. Pathomorphological changes in the right atrium wall of 4-month-old albino rats after treatment with pomegranate seed oil against the background of chronic pneumosclerosis of the research group. Stained with hematoxylin-eosin. OK 10 x 20 OB.1 - sparse focal and diffuse infiltrates consisting of neutrophils and eosinophilic granulocytes in the interstitial tissue of the myocardium, 2 - dimming of venous blood vessels due to erythrocyte mass, 3 - dystrophic changes in muscle fibers.

According to the results of the histomorphometric analysis, it was found that the dynamics of the histomorphometric parameters of the heart tissue cells of the right atrium and the right ventricle slightly exceeded the parameters of the control group.

Thus, during the study of the positive effect of pomegranate seed oil on the morphology of the heart of rats treated for 3 months against the background of pneumosclerosis, comparing the animals of this group of the study with the animals of the control group, although it did not cause macroscopically obvious pathological changes in the heart, however, it was observed to produce slightly different histological changes. In particular, it was noted that the diameter of cardiomyocytes in the heart myocardium increased to an insignificant level, and histologically, the changes manifested in the heart elements against the background of pneumosclerosis in 4-month-old white rats of the research group were confirmed by histomorphometric indicators.

1 – Table Comparative description of histomorphometric parameters in the heart of 4-month-old albino rats without drugs and after treatment with pomegranate seed oil against the background of chronic pneumosclerosis.

	Right atrium cardiomyocyte diameter (μm)	Left atrium cardiomyocyte diameter (μm)	Right ventricular cardiomyocyte diameter (μm)	Left ventricular cardiomyocyte diameter (μm)
The control group is 4 months old	8,44 \pm 0,08	9,67 \pm 0,2	9,05 \pm 0,07	12,83 \pm 0,07
The 2nd research group is 4 months old	8,48 \pm 0,1	9,7 \pm 0,14	9,26 \pm 0,31	12,86 \pm 0,17
The 3rd research group is 4 months old	8,46 \pm 0,06	9,68 \pm 0,16	9,19 \pm 0,21	12,85 \pm 0,15

In the visual examination, the heart of the 5-month-old rats of the 3rd research group treated with drugs was located in the chest cavity, and all parts except the front lower surface were covered with lungs.

3 - research group, the total body mass of the heart of 5-month-old rats is from 200.54 g to 209.56 g, the average is 202.63 \pm 0.66 g, the absolute heart mass is from 702.12 mg to 713.12 mg, the average is 708.86 \pm 0.76 mg, the relative mass of the heart in relation to 1 g of body mass is from 4.19 mg to 6.28 mg, the average is 5.21 \pm 0.13 mg, the length of the heart is 1.26 cm from 1.82 to 1.82, the average was 1.49 \pm 0.03 cm.

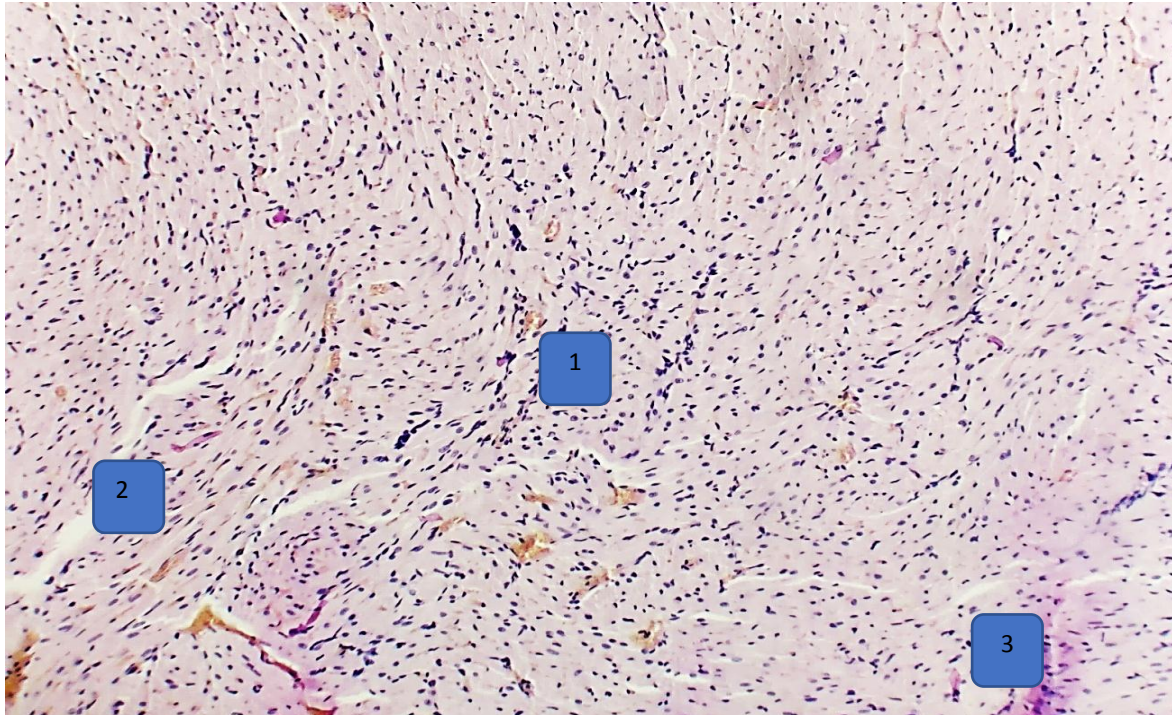
2 – Table Comparative description of histomorphometric parameters in the heart of 5-month-old albino rats without drugs and after treatment with pomegranate seed oil against the background of chronic pneumosclerosis.

	Right atrium cardiomyocyte diameter (μm)	Left atrium cardiomyocyte diameter (μm)	Right ventricular cardiomyocyte diameter (μm)	Left ventricular cardiomyocyte diameter (μm)
The control group is 5 months old	9,56 \pm 0,16	12,54 \pm 0,41	12,65 \pm 0,24	14,4 \pm 0,25
The second research group is 5 months old	9,64 \pm 0,14	12,62 \pm 0,27	13,03 \pm 0,16	14,47 \pm 0,2
The third research group is 5 months old	9,63 \pm 0,14	12,59 \pm 0,27	12,65 \pm 0,24	14,4 \pm 0,25

The diameter of right atrium cardiomyocytes is from 8.66 μm to 10.45 μm , with an average of 9.63 \pm 0.13 μm , the diameter of left atrium cardiomyocytes is from 10.21 μm to 14.47 μm , on average 12.59 \pm 0.27 μm , right ventricular cardiomyocyte diameter from 12.23 μm to 14.45 μm , on average 12.93 \pm 0.15 μm , left ventricular cardiomyocyte diameter 12.98 μm to 15.65 μm , the average was found to be 14.45 \pm 0.19 μm .

Macroscopically, after 3 months of pomegranate seed oil treatment against the background of chronic pneumosclerosis, 5-month-old white rats showed changes in the structure of the heart, especially the enlargement of the right atrium due to a slight swelling. However, as a result of the histological examination of the hearts of rats in the 3rd research group against the background of

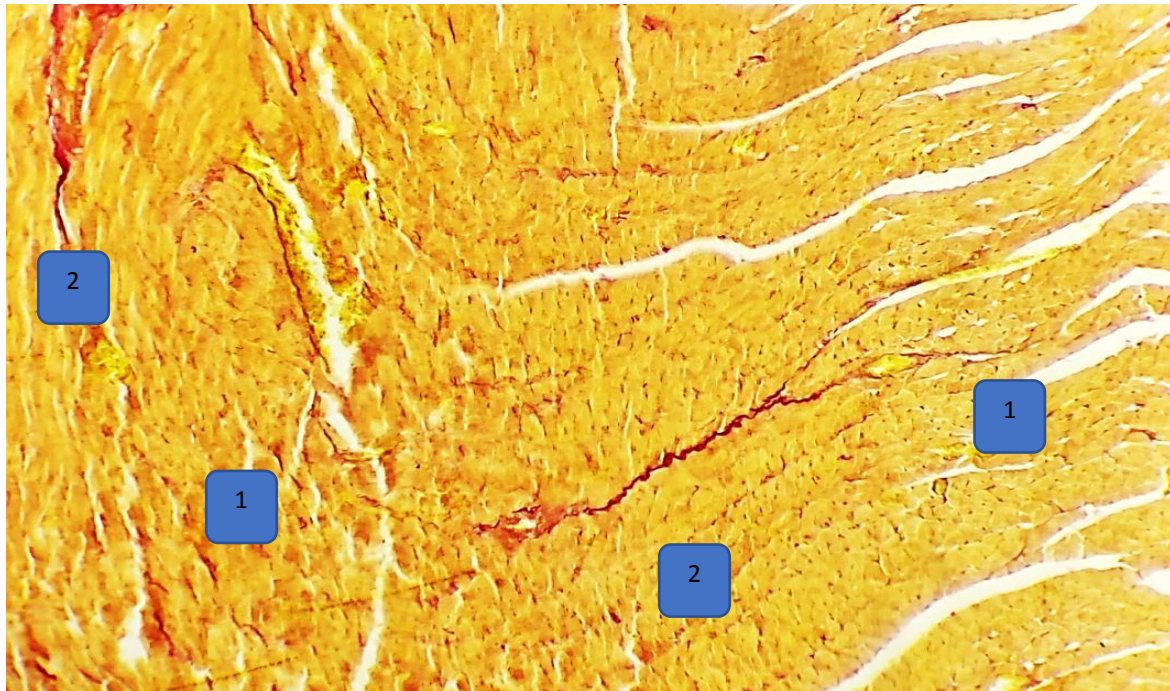
chronic pneumosclerosis, all the changes in the structure of the heart were less compared to the 2nd research group, which is a clear proof of the positive effect of pomegranate seed oil.



Picture 2. Pathomorphological changes in the right ventricular wall of 4-month-old albino rats after treatment with pomegranate seed oil against the background of chronic pneumosclerosis of the research group. Stained with hematoxylin-eosin. OK 10 x 20 OB. 1 - sparse diffuse infiltrates consisting of neutrophils and eosinophilic granulocytes in the interstitial tissue of the myocardium, 2 - edema in the interstitial space, 3 - dystrophic changes in muscle fibers.

Histologically, after 3 months of treatment in 5-month-old white rats of research group 3, cardiomyocytes in the myocardial layer of the heart preserved their structure, but with dystrophic changes in muscle fibers, mainly neutrophils and eosinophils in the interstitial tissue of the myocardium. Focal and diffuse infiltrates consisting of granulocytes, filling of venous blood vessels due to erythrocyte mass, as well as swelling due to the accumulation of aqueous solutions with low molecular proteins in the interstitial space due to increased permeability of blood vessels and damage to the endothelium of vessels less pathomorphological changes compared to the 2nd research group were found.

5-month-old white rats in research group 3 of the study showed obvious changes in the cells of the heart tissue of the right ventricle, and the reduction of these changes under the influence of pomegranate seed oil was confirmed by morphometric indicators.



Picture 3. Pathomorphological changes in the right ventricular wall of 5-month-old albino rats after treatment with pomegranate seed oil against the background of chronic pneumosclerosis of the 3rd research group. Stained with Van Gieson. OK 10 x 20 OB. 1- edema around the myocardial tissue, 2- sparse growth of connective tissue.

Thus, in the visual assessment of the effect of pomegranate seed oil treatment on the heart morphology of rats for 3 months against the background of chronic pneumosclerosis, the 5-month research group showed obvious differences in rats compared to the control group, namely, an increase in the diameter of cardiomyocytes in the myocardial layer of the heart's right ventricle and interstitial it was found that the swelling increased, but these indicators were less compared to the animals of the 2nd research group, where the drug was not used, and the lack of detection of pathomorphological foci such as focal and diffuse hemorrhage showed its positive effect. In order to eliminate the negative effects of chronic pneumosclerosis, the use of pomegranate seed oil as a treatment for 3 months had a positive effect on the organometric, histological and histomorphometric parameters of the heart of non-white rats of research group 3. The use of pomegranate seed oil for therapeutic purposes made it possible to significantly reduce the negative effects of all studied parameters.

The research showed that macroscopically, the hearts of 6-month-old white rats of study group 3 were located in the chest cavity, surrounded by lungs, and dense connective tissue on the outside, except for the front lower surface. It was covered by the epicardium, which was made up of meatus, and it was found that the right lobe, especially the right ventricle, was slightly shifted to the left.

During the observation, in the study of the organometric parameters of the heart of rats of this group, the total total body mass was from 200.92 g to 217.7 g, the average was 209.23 ± 1.05 g, the absolute heart mass was 733.12 mg to 748 , up to 12 mg, the average is 737.67 ± 1.07 mg, the relative mass of the heart in relation to 1 g of body mass is from 5.66 mg to 6.48 mg, the average is 5.91 ± 0.05 mg, heart length ranged from 1.38 to 1.72 cm, the average was 1.57 ± 0.03 cm.

3 - research group, in the myocardial layer of the heart of 6-month-old white purebred rats, cardiomyocytes are located in the form of parallel bundles, and it was found that the cardiomyocytes of the right and left ventricles are smaller in size and freely located compared to the cardiomyocytes of the right and left ventricles.

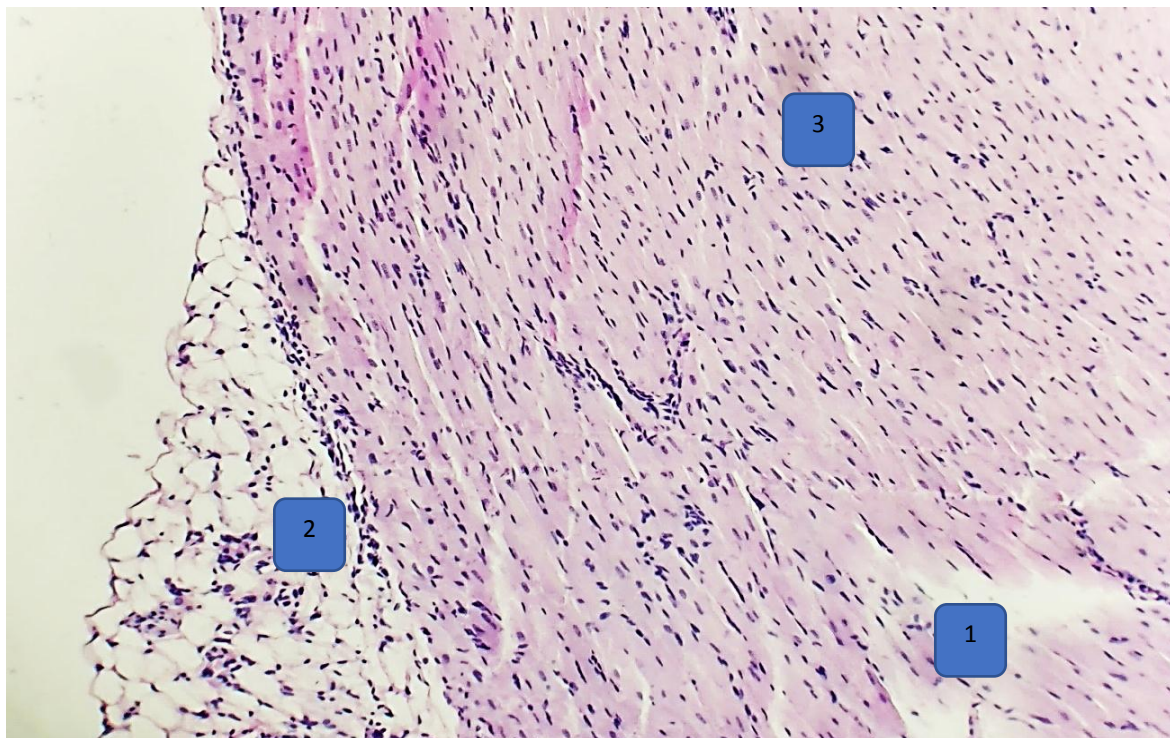
In this case, the diameter of right atrium cardiomyocytes is from $9.75 \mu\text{m}$ to $11.71 \mu\text{m}$, on average $10.74 \pm 0.17 \mu\text{m}$, the diameter of left atrium cardiomyocytes is from $11.21 \mu\text{m}$ to $16.7 \mu\text{m}$, on average $13.12 \pm 0.45 \mu\text{m}$, right ventricular cardiomyocyte diameter from $11.41 \mu\text{m}$ to $15.78 \mu\text{m}$, on average

13.1±0.3 μm, left ventricular cardiomyocyte diameter 12.45 From μm to 16.4 μm, the average was 14.62±0.28 μm.

3 – Table Comparative description of histomorphometric parameters in the heart of 6-month-old albino rats without drugs and after treatment with pomegranate seed oil against the background of chronic pneumosclerosis.

	Right atrium cardiomyocyte diameter (μm)	Left atrium cardiomyocyte diameter (μm)	Right ventricular cardiomyocyte diameter (μm)	Left ventricular cardiomyocyte diameter (μm)
The control group is 6 months old	10,66±0,3	13,08±2,08	12,69±0,24	14,59±0,32
The second research group is 6 months old	10,81±0,18	13,2±0,4	13,3±0,25	14,67±0,25
The third research group is 6 months old	10,74±0,17	13,12±0,26	13,14±0,29	14,62±0,28

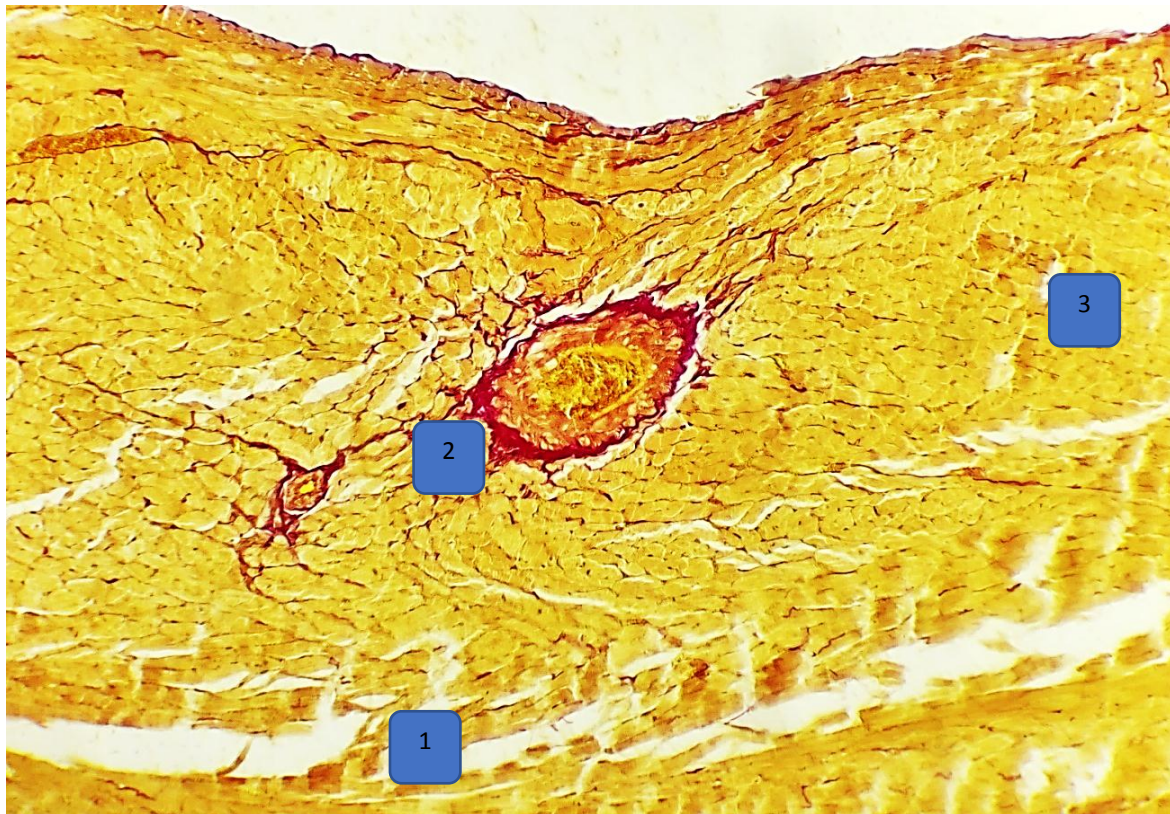
Research group 3 of the study showed that after 3 months of treatment with pomegranate seed oil in the background of chronic pneumosclerosis, the histological examination of the heart of 6-month-old purebred rats showed that the number of right atrium and right ventricular heart tissue cells it was found that such changes in histological parameters were slightly higher than the histological parameters of the heart of the animals in the 1st control group, but less than the changes in the histological parameters of the hearts of the animals in the 2nd research group.



Picture 4. Pathomorphological changes in the right ventricular wall of 4-month-old albino rats after treatment with pomegranate seed oil against the background of chronic pneumosclerosis of the research group. Stained with hematoxylin-eosin. OK 10 x 20 OB.1 - swellings in the interstitial tissue of the myocardium, 2 - growth of adipose tissue due to dystrophic changes in cardiomyocytes, 3 - dystrophic changes in muscle fibers.

Morphologically, after 3 months of treatment with pomegranate seed oil in 6-month-old white rats, the cardiomyocytes in the myocardial layer of the heart of the experimental animals preserved their structure, but with dystrophic changes in the muscle fibers. At the same time, among the interstitial tissue of the myocardial layer consisting of cellular elements, focal and diffuse infiltrates consisting mainly of neutrophils and eosinophilic granulocytes, fullness and dimming of venous blood vessels due to erythrocyte mass, as well as increased vascular permeability and due to damage to the

vascular endothelium, due to the accumulation of aqueous solutions with low-molecular proteins in the interstitial space, the pathomorphological changes such as edema, karyolysis and cytolysis of cardiomyocytes were not used. and 1 - it was found that it approached the indicators of the control group.

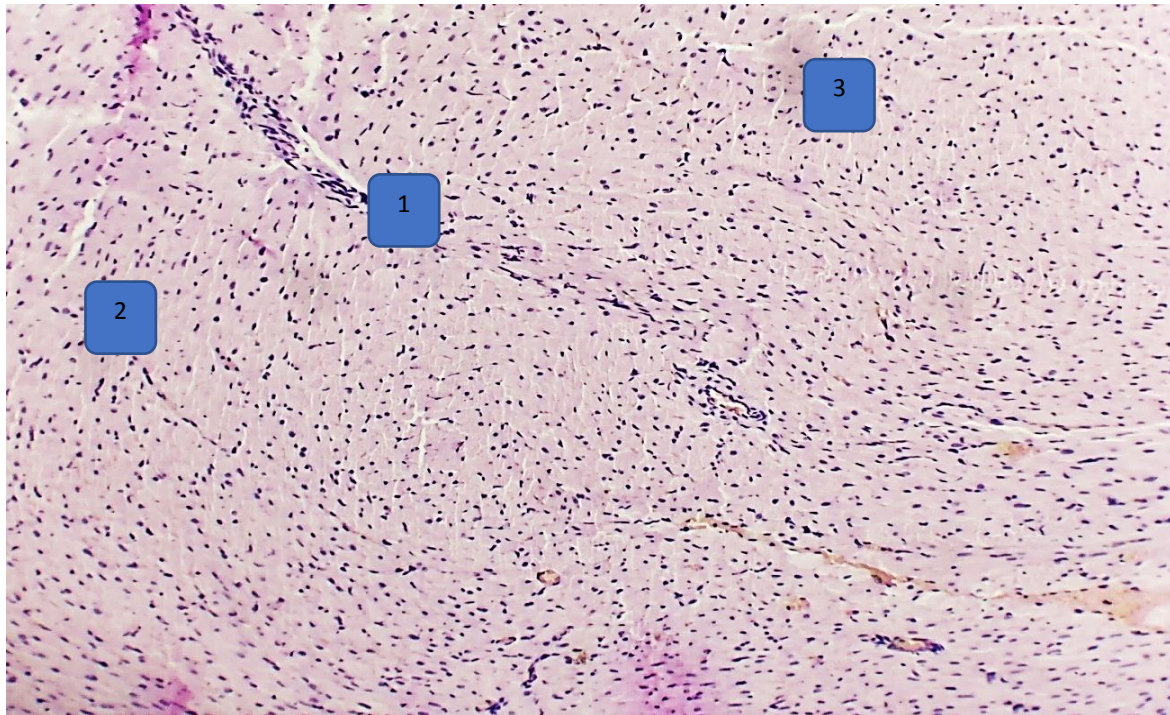


Picture 5. Morphological changes in the right atrium wall of 4-month-old purebred rats after treatment with pomegranate seed oil against the background of chronic pneumosclerosis of the research group. Stained with hematoxylin-eosin. OK 10 x 20 OB. 1- swellings around the myocardial tissue, 2- sparse growth of connective tissue, 3- dystrophic changes of cardiomyocytes.

Thus, during the study of the positive effect of pomegranate seed oil on the morphology of the heart, which was used for 3 months for the purpose of treatment against the background of pneumosclerosis in white rats of research group 3, when comparing the animals of this research group with the animals of the control group, macroscopic changes in the heart were observed. due to a slight enlargement of the right ventricle, the organs of the thoracic cavity were slightly shifted to the left and histologically it caused slightly different changes, but these indicators were not applied to the animals of the 2nd research group Its positive effect was shown by its relatively small number, non-detection of pathomorphological foci such as focal and diffuse hemorrhage. Pomegranate seed oil used for 3 months to eliminate the negative effects of chronic pneumosclerosis showed a positive effect on the organometric, histological and histomorphometric parameters of the heart of non-white rats in research group 3, and the use of pomegranate seed oil for therapeutic purposes, made it possible to significantly mitigate the negative effects of all studied parameters.

In the visual inspection, the heart of the 7-month-old rats of the 3rd study group treated with drugs was located in the chest cavity, and all parts except the front lower surface were covered with lungs. It was observed that the organs of the thoracic cavity were slightly shifted to the left due to the enlargement of the heart of the rats, mainly the right atrium and the right ventricle.

3 - research group, the total body mass of the heart of 7-month-old rats is from 206.77 g to 225.22 g, the average is 216.12 ± 1.41 g, the absolute heart mass is from 753.98 mg to 787.5 mg, on average 774.1 ± 3.27 mg, the relative mass of the heart per 1 g of body mass is from 6.91 mg to 9.1 mg, on average 8.03 ± 0.15 mg, heart length is 1.57 cm from 2.17 to 2.17, the average was 1.78 ± 0.04 cm.



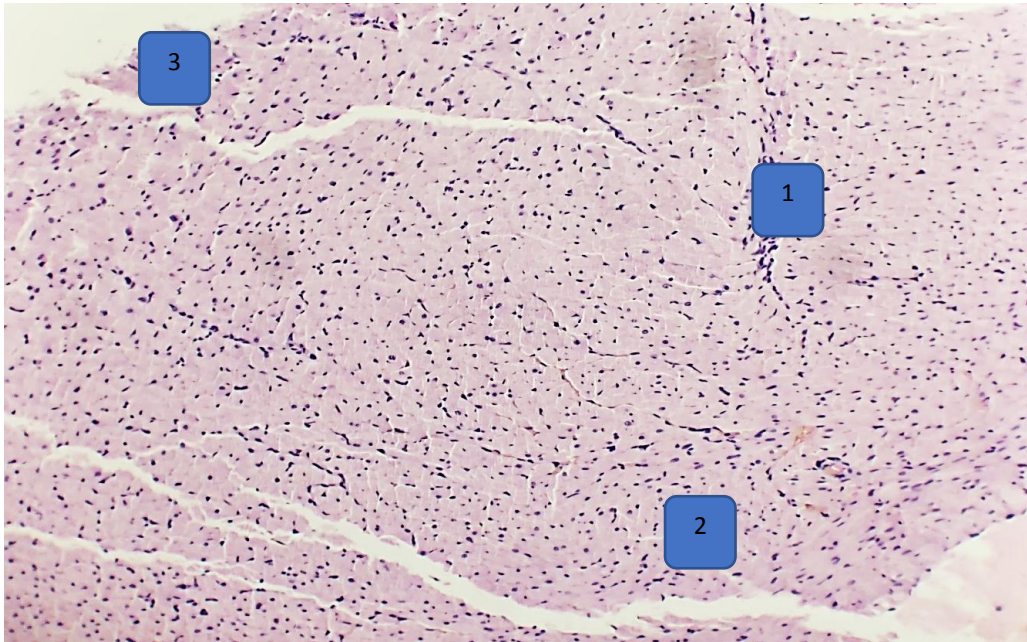
Picture 6. Pathomorphological changes in the right atrium wall of 4-month-old albino rats after treatment with pomegranate seed oil against the background of chronic pneumosclerosis of the research group. Stained with hematoxylin-eosin. OK 10 x 20 OB. 1 - sparse diffuse infiltrates consisting of neutrophils and eosinophilic granulocytes in the interstitial tissue of the myocardium, 2 - edema in the interstitial space, 3 - dystrophic changes in muscle fibers.

The diameter of right atrium cardiomyocytes is from 10.75 μm to 15.1 μm , on average $12.14 \pm 0.36 \mu\text{m}$, the diameter of left atrium cardiomyocytes is from 13.62 μm to 19.97 μm , on average $17.1 \pm 0.35 \mu\text{m}$, right ventricular cardiomyocyte diameter from 11.38 μm to 17.51 μm , on average $13.92 \pm 0.56 \mu\text{m}$, left ventricular cardiomyocyte diameter 15.98 μm to 18.98 μm , the average was found to be $17.41 \pm 0.23 \mu\text{m}$.

4 – Table Comparative description of histomorphometric parameters in the heart of 7-month-old albino rats without drugs and after treatment with pomegranate seed oil against the background of chronic pneumosclerosis.

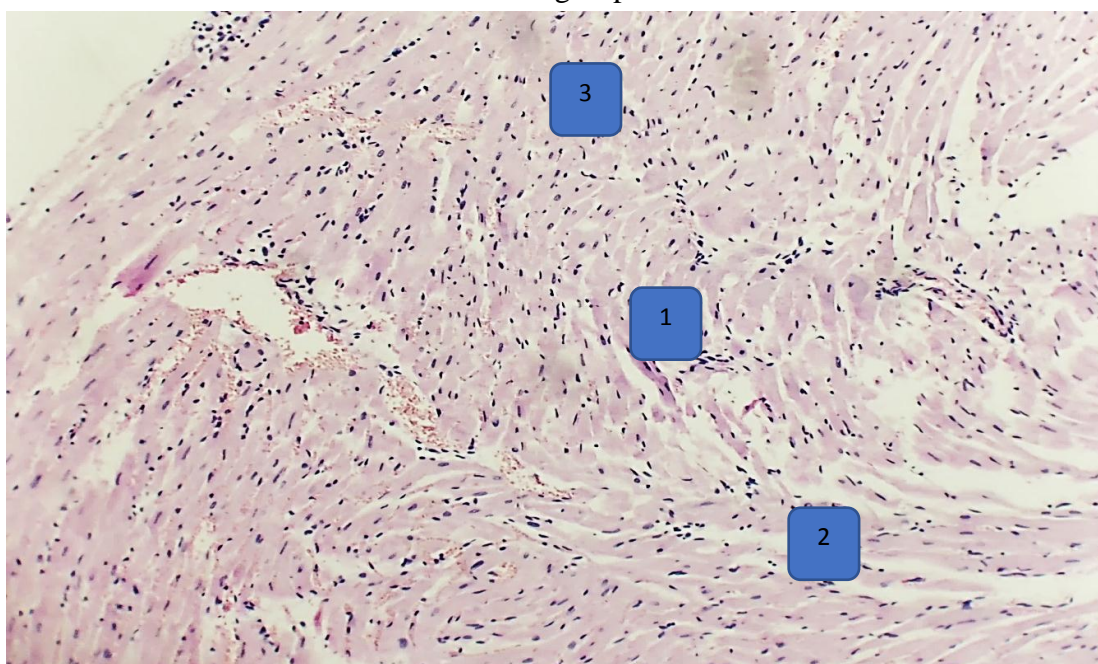
	Right atrium cardiomyocyte diameter (μm)	Left atrium cardiomyocyte diameter (μm)	Right ventricular cardiomyocyte diameter (μm)	Left ventricular cardiomyocyte diameter (μm)
The control group is 7 months old	$11,84 \pm 0,23$	$16,85 \pm 0,36$	$13,3 \pm 0,29$	$17,21 \pm 0,29$
The second research group is 7 months old	$12,3 \pm 0,34$	$17,3 \pm 0,25$	$14,4 \pm 0,4$	$17,6 \pm 0,2$
The third research group is 7 months old	$12,14 \pm 0,36$	$16,85 \pm 0,36$	$13,3 \pm 0,29$	$17,21 \pm 0,29$

Macroscopically, after treatment with pomegranate seed oil for 3 months in the background of chronic pneumosclerosis, 7-month-old albino rats showed no obvious significant changes in heart structure, left atrium, and left ventricle, but the right atrium and right ventricle observed changes, such as a slight enlargement of the ventricle due to interstitial edema. However, as a result of the use of medical measures for 3 months against the background of chronic pneumosclerosis, the animals of this 3-research group showed all the observed changes in the structure of the heart in the histological examination, compared to the 2-research group, and the animals of the 1-control group showed these indicators. approaching the signs is a clear proof of the positive effect of pomegranate seed oil.



Picture 7. Pathomorphological changes in the right atrium wall of 4-month-old albino rats after treatment with pomegranate seed oil against the background of chronic pneumosclerosis of the research group. Stained with hematoxylin-eosin. OK 10 x 20 OB. 1 - sparse diffuse infiltrates consisting of neutrophils and eosinophilic granulocytes in the interstitial tissue of the myocardium, 2 - edema in the interstitial space, 3 - dystrophic changes in muscle fibers.

Histologically, after treatment with pomegranate seed oil in 7-month-old white rats of research group 3, cardiomyocytes in the myocardial layer of the heart of experimental animals preserved their structure, but their diameter increased in volume, muscle fibers were dystrophic. along with the changes, there are focal and diffuse infiltrates mainly composed of neutrophils and eosinophilic granulocytes among the interstitial tissue of the myocardial layer, fullness and dimming of venous blood vessels due to erythrocyte mass, as well as an increase in vascular permeability and vascular endothelium Due to injury, no treatment measures were used for pathomorphological changes such as edema, thickening of the wall of myocardial vessels, karyolysis and cytolysis of cardiomyocytes due to the accumulation of fluids in the interstitial space with low molecular proteins. 2 - research group compared to histological indicators in 6-month-old white rats it was found that it decreased, and it was close to the indicators of the 1 - control group.

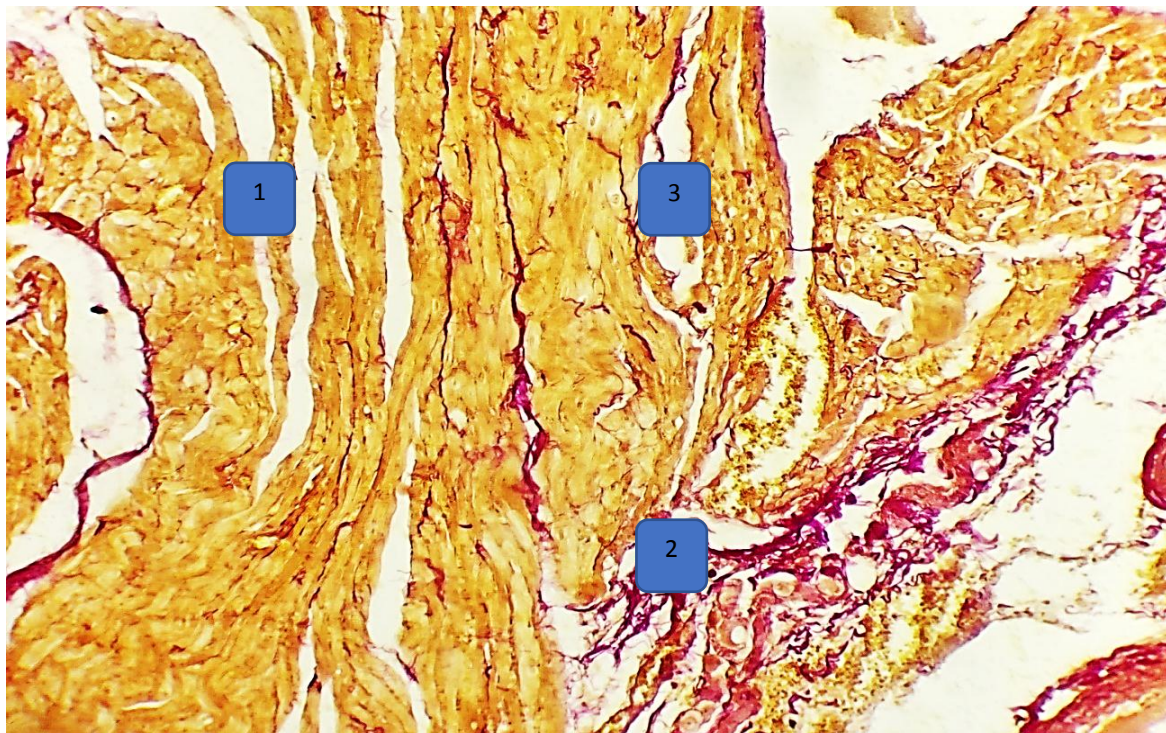


Picture 8. Pathomorphological changes in the right atrium wall of 4-month-old albino rats after treatment with pomegranate seed oil against the background of chronic pneumosclerosis of the

research group. Stained with hematoxylin-eosin. OK 10 x 20 OB.1 - sparse diffuse infiltrates consisting of neutrophils and eosinophilic granulocytes in the interstitial tissue of the myocardium, 2 - edema in the interstitial space, 3 - dystrophic changes in muscle fibers.

7-month-old animals in research group 3 of the study showed obvious changes in the cells of the heart tissue of the right atrium and right ventricle, and the reduction of these changes under the influence of pomegranate seed oil was confirmed by morphometric indicators.

Thus, in the macroscopic visual assessment of the effect of pomegranate seed oil treatment on the heart morphology of study group 3 rats for 3 months against the background of chronic pneumosclerosis, the changes in the 7-month-old animals compared to the control group were found to be clearly different, that is, mainly the right side of the heart. It was found that the diameter of the cardiomyocytes in the right atrium and the right ventricle was increased due to the increase in the diameter of the cardiomyocytes and interstitial edema, but these indicators were less compared to the animals of the 2nd research group, which did not receive the drug, and the pathomorphological foci such as focal and diffuse hemorrhage its indeterminacy showed its positive effect. In order to eliminate the negative effects of chronic pneumosclerosis, the use of pomegranate seed oil as a treatment for 3 months had a positive effect on the organometric, histological and histomorphometric parameters of the rat heart in the 7-month research group. The use of pomegranate seed oil for the purpose of treatment against the background of chronic pneumosclerosis made it possible to significantly reduce the negative effects of all studied parameters.



Picture 9. Morphological changes in the right atrium wall of 4-month-old purebred rats after treatment with pomegranate seed oil against the background of chronic pneumosclerosis of the research group. Stained with hematoxylin-eosin. OK 10 x 20 OB.1- swellings around the myocardial tissue, 2- sparse growth of connective tissue, 3- dystrophic changes of cardiomyocytes.

5 – Table Comparative description of histomorphometric parameters in the heart of 7- and 8-month-old albino rats without drugs and after treatment with pomegranate seed oil against the background of chronic pneumosclerosis.

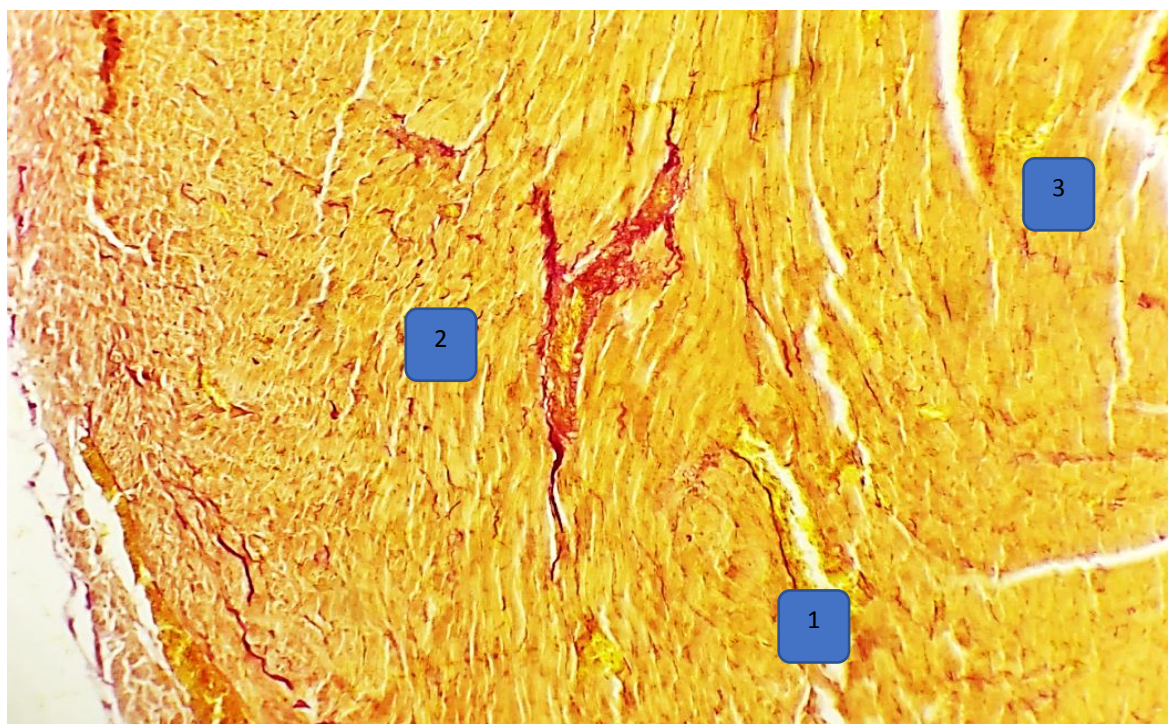
	Right atrium cardiomyocyte diameter (μm)	Left atrium cardiomyocyte diameter (μm)	Right ventricular cardiomyocyte diameter (μm)	Left ventricular cardiomyocyte diameter (μm)
The control group is 7 months old	11,84 \pm 0,23	16,85 \pm 0,36	13,3 \pm 0,29	17,21 \pm 0,29

The second research group is 7 months old	12,3±0,34	17,3±0,25	14,4±0,4	17,6±0,2
The third research group is 7 months old	12,14±0,36	17,07±0,35	13,92±0,56	17,42±0,23
The control group is 8 months old	13,84±0,3	19,5±0,36	15,71±0,25	20,41±0,42
The second research group is 8 months old	14,8±0,3	20,24±0,35	17,32±0,3	21,15±0,45
The third research group is 8 months old	14,27±0,3	19,84±0,32	16,33±0,6	20,88±0,44

The research showed that macroscopically, the hearts of 8-month-old white rats of study group 3 were located in the chest cavity, surrounded by lungs, and dense connective tissue on the outside, except for the front lower surface. It was covered with epicardium composed of axilla, especially due to the enlargement of the right atrium and ventricle, it was observed that the organs of the thoracic cavity were slightly shifted to the left.

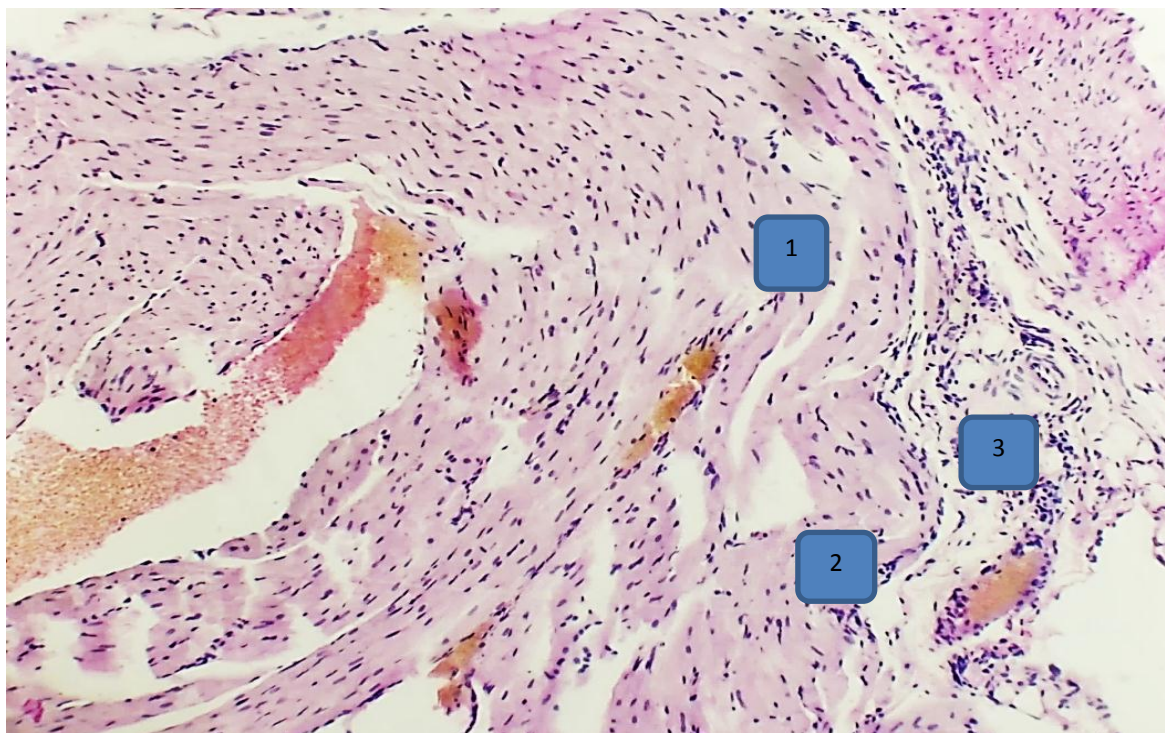
During the study, in the study of the organometric parameters of the heart of rats of this group, the total total body mass was from 220.54 g to 235.92 g, the average was 230.4 ± 1.03 g, the absolute heart mass was from 806.12 mg to 816 , up to 12 mg, the average is 809.37 ± 0.73 mg, the relative mass of the heart in relation to 1 g of body mass is from 8.28 mg to 12.11 mg, the average is 9.84 ± 0.32 mg, heart length ranged from 1.66 to 2.37 cm, the average was 1.93 ± 0.04 cm.

It was observed that cardiomyocytes are located in the form of parallel bunches in the myocardial layer of the heart of the 8-month-old research group 3, the cardiomyocytes of the right and left atrium, and the cardiomyocytes of the right and left ventricles are small in size and freely located.



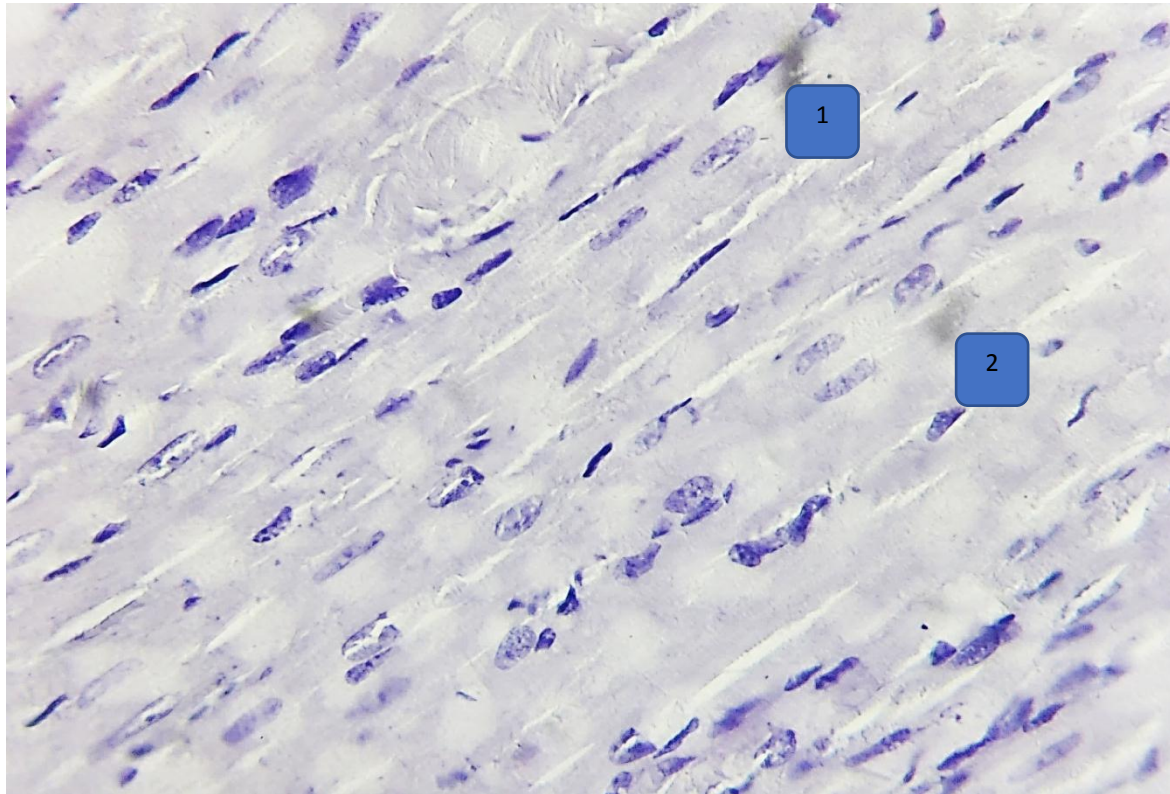
Picture 10. 3 - morphological changes in the right ventricular wall of the heart of 8-month-old purebred white rats after treatment with pomegranate seed oil against the background of chronic pneumosclerosis of the research group. Stained with Van Gieson. OK 10 x 20 OB. 1- swellings around the myocardial tissue, 2- sparse growth of connective tissue, 3- dystrophic changes of cardiomyocytes.

In this case, the diameter of right atrium cardiomyocytes is from 12.65 μm to 15.8 μm , on average 14.27 \pm 0.29 μm , the diameter of left atrium cardiomyocytes is from 18.71 μm to 23.7 μm , 19.84 \pm 0.32 μm on average, right ventricular cardiomyocyte diameter from 13.23 μm to 19.45 μm , on average 16.5 \pm 0.48 μm , left ventricular cardiomyocyte diameter 17.64 From μm to 24.87 μm , the average was 20.88 \pm 0.44 μm .



Picture 11. Morphological changes in the right atrium wall of 4-month-old purebred rats after treatment with pomegranate seed oil against the background of chronic pneumosclerosis of the research group. Stained with hematoxylin-eosin. OK 10 x 20 OB. 1 - swellings in the interstitial tissue of the myocardium, 2 - swelling of venous blood vessels due to erythrocyte mass, 3 - dystrophic changes in muscle fibers.

According to the histological examination of the heart of 6-month-old purebred rats, no changes occurred in the left atrium and left ventricle after 3 months of treatment with pomegranate seed oil against the background of chronic pneumosclerosis in research group 3 but mainly the changes in the histological parameters of cardiomyocytes in the heart tissue of the right atrium and the right ventricle are slightly higher than the histological parameters of the heart of animals in the 1st control group, but less than the changes in the histological parameters of the heart of animals in the 2nd research group was found to be.



Picture12. Morphological changes in the right atrium wall of 4-month-old purebred rats after treatment with pomegranate seed oil against the background of chronic pneumosclerosis of the research group. Stained with hematoxylin-eosin. OK 40 x 20 OB.1 - swellings in the interstitial tissue of the myocardium, 2 - dystrophic changes in muscle fibers.

Histologically, after 3 months of treatment with pomegranate seed oil in 8-month-old white rats of research group 3, the cardiomyocytes in the myocardial layer of the heart of the experimental animals preserved their structure, but with dystrophic changes in the muscle fibers. focal and diffuse infiltrates mainly composed of neutrophils and eosinophilic granulocytes among the interstitial tissue of the myocardial layer, fullness and dimming of venous blood vessels due to erythrocyte mass, thickening of the vessel wall, as well as increased permeability of blood vessels and interstitial due to damage to the endothelium of vessels due to the accumulation of aqueous solutions with low-molecular proteins in the cavity, various pathomorphological changes in the form of edema, cardiomyocyte karyolysis and cytolysis focal necrosis were not applied, compared to the histological indicators of research group 2 in 8-month-old white rats, and 1 - it was proved that it approached the indicators of the control group.

Thus, during the study of the positive effect of pomegranate seed oil on the heart morphology, which was used for 3 months for the purpose of treatment in white rats of the 3rd research group against the background of chronic pneumosclerosis disease, comparing the animals of this research group with the animals of the 1st control group, macroscopically in the heart, due to a slight enlargement of the right ventricle, a slight shift of the thoracic cavity to the left and histologically, it causes slightly different changes, but these indicators were not used by the drug 2 - Its positive effect was shown by the lack of detection of pathomorphological foci, such as focal and diffuse hemorrhage, compared to the animals of the research group.

Pomegranate seed oil used for 3 months to eliminate the negative effects of chronic pneumosclerosis showed a positive effect on the organometric, histological and histomorphometric parameters of the heart of non-white rats in research group 3, and the use of pomegranate seed oil for therapeutic purposes, made it possible to significantly mitigate the negative effects of all studied parameters.

The obvious organometric and histological changes manifested in heart elements against the background of pneumosclerosis in 8-month-old white rats of the research group were confirmed by histomorphometric indicators.

In conclusion, during the study of the positive effect of pomegranate seed oil on heart morphology, which was used for 3 months for the purpose of treatment against the background of chronic pneumosclerosis, comparing the animals of this research group with the animals of the 1st control group, 2nd research group white The minimal changes in the histological and histomorphometric parameters of the tissue elements of the heart of inbred rats were recorded in the body of 4-month-old rats of the experimental group, and the maximum changes were recorded in the body of the 8-month-old rats of the experimental group. made it possible to significantly reduce the negative effects of the studied parameters.

During the study, statistically significant differences were found in all studied organometric and morphometric indicators, compared to the indicators of the control group of animals of the 2nd and 3rd research groups.

Literature

1. Aysanov Z.R., Chernyak A.V., Kalmanova Ye.N. Spirometriya v diagnostike i otsenke terapii khronicheskoy obstruktivnoy bolezni legkix v obshchegachebnoy praktike. *Pulmonologiya*. 2014; 5: 101-110
2. Baymakanova G.E., Avdeev S.N. Diagnosticheskaya i prognosticheskaya rol povysheniya biomarkerov povrejdeniya (troponina I, belka, svyazyvayushchego jirnye kisloty) pri obostrenii khronicheskoy obstruktivnoy bolezni legkix. *Pulmonologiya* 2012; 1: 66–74.
3. Bondarev O.I., Bugaeva M.S., Mixaylova N.N. Spesifichnost morfologicheskix izmeneniy v organax i tkanyax na vozdeystvie razlichnykh proizvodstvennykh faktorov (eksperimentalnye issledovaniya) // Vliyanie okruzhayushchey i proizvodstvennoy sredy na zdorove cheloveka. Puti resheniya problem: mat. XLVII nauch.-prakt. konf. «Gigiena, organizatsiya zdravooxraneniya i profpatologiya» i seminar «Aktualnye voprosy sovremennoy profpatologii» / pod red. V.V. Zaxarenkova. Kemerovo: Primula, 2012. S. 42–44.
4. Bondarev O.I., Bugaeva M.S., Mixaylova N.N., Filimonov S.N. Osobennosti strukturnoy dezorganizatsii kollagena kak puskovogo mexanizma pnevmoskleroza u shaxterov. *Med. truda i prom. ekol.* 2018. 6: 7–11.
5. Bubnova M.G., Aronov D.M. COVID-19 i serdechno-sosudistyye zabolevaniya: ot epidemiologii do reabilitatsii. *Pulmonologiya*. 2020; 30 (5): 688–699.
6. Kanorskiy S.G. COVID-19 i serdse: pryamoe i kosvennoe vliyanie. *Kubanskiy nauchnyy meditsinskiy vestnik*. 2021; 28(1): 16–31.
7. Krivenko Lyudmila Yevgenevna, Polushin O.G., Vud T.G., Sherstneva Ye.P. Morfologicheskie izmeneniya v legkix pri khronicheskoy intoksikatsii xromom // *TMJ*. 2014. №1 (55).
8. Leshenko I.V., Glushkova T.V. O funktsionalnykh narusheniyax i razvitiy fibroza legkix u bolnykh, perenesshix novuyu koronavirusnyuyu infektsiyu. *Pulmonologiya*. 2021; 31 (5): 653–662.
9. Mamedov M.N., Rodionova Yu.V., Yavelov I.S., Smirnova M.I., Dudinskaya Ye.N., Potievskaya V.I. Koronavirusnaya infektsiya s tochki zreniya mejdissiplinarnogo podxoda. *Kruglyy stol. Kardiovaskulyarnaya terapiya i profilaktika*. 2021;20(3):2849.
10. Mixaylova Nadejda Nikolaevna, Bondarev Oleg Ivanovich, Bugaeva Mariya Sergeevna Patomorfologicheskie izmeneniya sosudov serdsa i legkix pri pnevmokonioze // *MvK*. 2017. №3.
11. Shomurodova Mukhayo Rakhmonovna, (May 6, 2023). Morphological Features and Morphometric Parameters of the Lungs after Correction with an Immunomodulator under the Conditions of Experimental Chemotherapy. *Journal of Natural and Medical Education* (pp. 55-60).