



## Results of Coronary Artery Stenting in Elderly People with Chronic Heart Failure

Yarasheva Zarrina Khikmatillaevna<sup>1</sup>, Rustamova Sarvinoz Botir Kizi<sup>2</sup>

1 Samarkand State Medical University, Republic of Uzbekistan, Samarkand

2 Republican specialized cardiology scientific-practical medical center Samarkand regional branch

**Abstract:** Coronary artery disease (CHD) is widespread among patients with heart failure (HF) and accounts for almost two-thirds of cases. The use of percutaneous coronary intervention (PCI) in patients with CAD has increased markedly, and numerous observational studies have suggested that it is associated with improved patient outcomes (Puja B. Parikh, MD, MPH, Deepak L. Bhatt, MD, MPH et al, 2021). There are no randomized data comparing the impact of PCI on clinical outcomes and myocardial deremodeling in patients with coronary artery disease with coronary artery stenting or modern drug therapy aimed at compliance. There is evidence of the effect of PCI in acute MI (with and without acute coronary syndrome), chronic CAD with reduced ejection fraction, and MI with preserved ejection fraction. Randomized clinical trials with sufficient confirmation are needed to study the outcomes of PCI in these various populations of patients with coronary artery disease. (J Am Coll Cardiol 2021;77:2432-47) © 2021 American College of Cardiology Foundation.

**Keywords:** chronic heart failure, percutaneous coronary intervention, coronary artery stenting, echocardiography, natriuretic peptide.

### Relevance

Ischemic heart disease (CHD) remains the most common cause of heart failure (HF) in Uzbekistan, accounting for 60% to 70% of cases [1,3]. Coronary artery bypass surgery (CABG) is and remains in recent years the main method of treatment of multivessel coronary artery disease with concomitant left ventricular systolic dysfunction (LVSD) for several decades [4,5]. However, at present, advanced and complex multivessel percutaneous coronary interventions (PCI) using the latest antiplatelet therapy and percutaneous mechanical circulatory support, the impact of PCI on patients with acute and chronic heart failure with reduced ejection fraction (HFEF), as well as heart failure with preserved fraction emissions (HFpEF) has become a subject of increased interest.

American studies reported that after revascularization in stable CAD with severe LV EF, an increase in LV EF was observed in 50% of patients [6,7]. Pooled data from the PROTECT II registry (a prospective, multicenter, randomized, controlled trial of the IMPELLA RECOVER LP 2.5 system versus an intra-aortic balloon pump in patients undergoing high-risk elective PCI) and the cVAD (ventricular assisted catheter devices) registry showed that 57% of patients after PCI with hemodynamic support, there was an improvement in LV EF by at least 5% [8]. Mean LVEF improved from 25% to 31% after PCI (6.5% net increase  $p < 0.001$ ), and greater improvement in LVEF was directly correlated with more vessels treated[8]. One small study of revascularized patients with stable CAD, reduced LV EF and no implantable cardioverter defibrillator (ICD) found that 56% of these patients were no longer candidates for an ICD based on improved LV EF at follow-up [7]. In the PROTECT II substudy, 51% demonstrated reverse LV remodeling with an absolute increase in LVEF of 13% ( $p < 0.001$ ) and a decrease in end-systolic volume [6]. Reverse LV

remodeling occurred more frequently in patients with more extensive revascularization (RR: 7.52; 95% CI: 1.31–43.25) and was associated with significantly fewer major adverse cardiovascular and cerebrovascular events (9.7% vs 24.2%,  $p < 0.001$ ),

Pooled data from PROTECT II and the cVAD registry showed that more treated vessels were independently associated with greater improvement in LVEF (5.5% improvement in LVEF with 1 vessel treatment, 6.6% with 2 vessel treatment, 8.3% for 3-vessel treatment [ $p$  for trend  $< 0.046$ ]) [8]. Data from the CHART-2 study (Chronic Heart Failure Analysis and Registry in the Tohoku District-2) demonstrated that in patients with symptomatic heart failure and a history of PCI, approximately two-thirds of patients had residual stenosis (defined as the presence of residual  $\geq 70\%$  neovascular stenosis) [9]. Patients with residual stenosis had a higher all-cause mortality than those without, even after density matching (21.9% vs. 11.6%; log-rank  $p < 0.027$ ). Residual stenosis was independently associated with all-cause mortality in patients with ischemic heart disease (HR: 1.62; 95% CI: 1.07–2.46;  $p < 0.024$ ) [9]. Complete revascularization in patients with HF can sometimes be technically challenging. In patients with HFrEF, failure of a total revascularization attempt due to hemodynamic instability, difficulty in performing chronic total occlusion (CTO), presence of non-dilated lesions, or procedural complications was associated with higher rates of short-term and long-term major adverse cardiac events compared with successful total revascularization and selective incomplete revascularization [10,11]. Complete revascularization in patients with HF can sometimes be technically challenging. In patients with HFrEF, failure of a total revascularization attempt due to hemodynamic instability, difficulty in performing chronic total occlusion (CTO), presence of non-dilated lesions, or procedural complications was associated with higher rates of short-term and long-term major adverse cardiac events compared with successful total revascularization and selective incomplete revascularization [10,11]. Complete revascularization in patients with HF can sometimes be technically challenging. In patients with HFrEF, failure of a total revascularization attempt due to hemodynamic instability, difficulty in performing chronic total occlusion (CTO), presence of non-dilated lesions, or procedural complications was associated with higher rates of short-term and long-term major adverse cardiac events compared with successful total revascularization and selective incomplete revascularization [10,11].

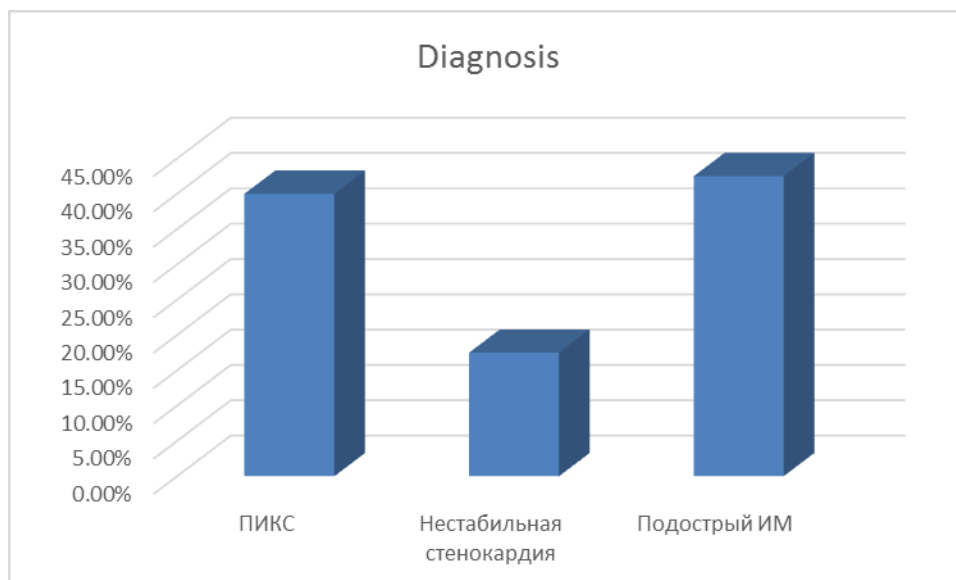
**Target:** To evaluate the benefits of percutaneous coronary intervention (PCI) in reducing NT-proBNP and increasing the left ventricular ejection fraction in elderly patients.

**Materials and methods:** We analyzed elderly patients who underwent PCI from September 1 to March 1, 2022 according to the data of the Samarkand Regional Branch of the Republican Specialized Scientific and Practical Medical Center for Cardiology. A total of 80 patients were analyzed, who underwent interventional intervention (PCI) with a radical approach 58.75% ( $n=74$ ) and other approaches 3.68% ( $n=6$ ). Men accounted for 68.1% ( $n=43$ ), women 31.9% ( $n=37$ ). The mean age was 63.46.

Before PCI, all patients were examined by a cardiologist and prescribed general and biochemical blood tests, blood NT-proBNP levels, ECG, echocardiography, chest x-ray, and coronary angiography.

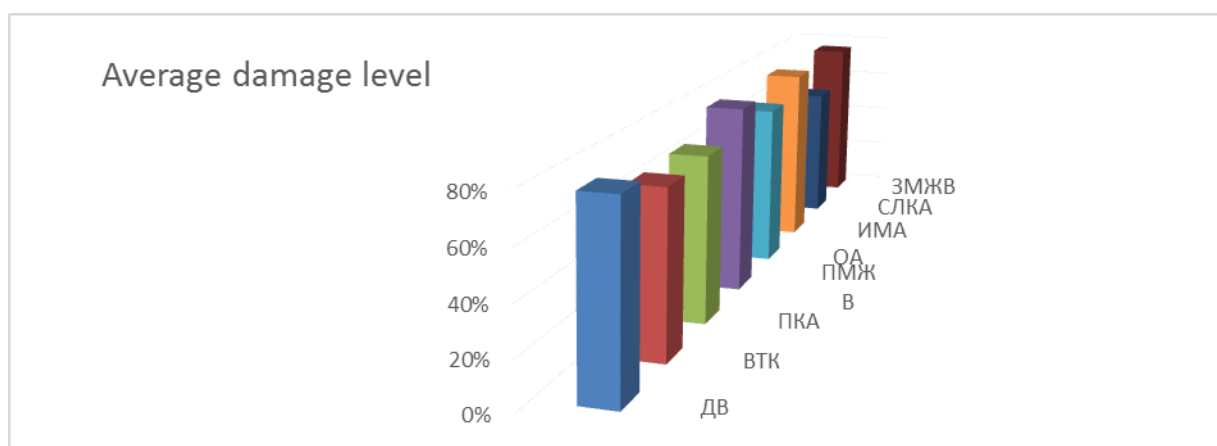
The main part of the patients was diagnosed with coronary artery disease: postinfarction atherosclerosis (PICS) - 40% ( $n=32$ ), with subacute myocardial infarction 42.5% ( $n=34$ ), unstable angina FC 3-4 17.5% ( $n=14$ ). The distribution of patients by diagnosis is shown in diagram No. 2.

**Diagram №1. Distribution of patients by diagnosis**



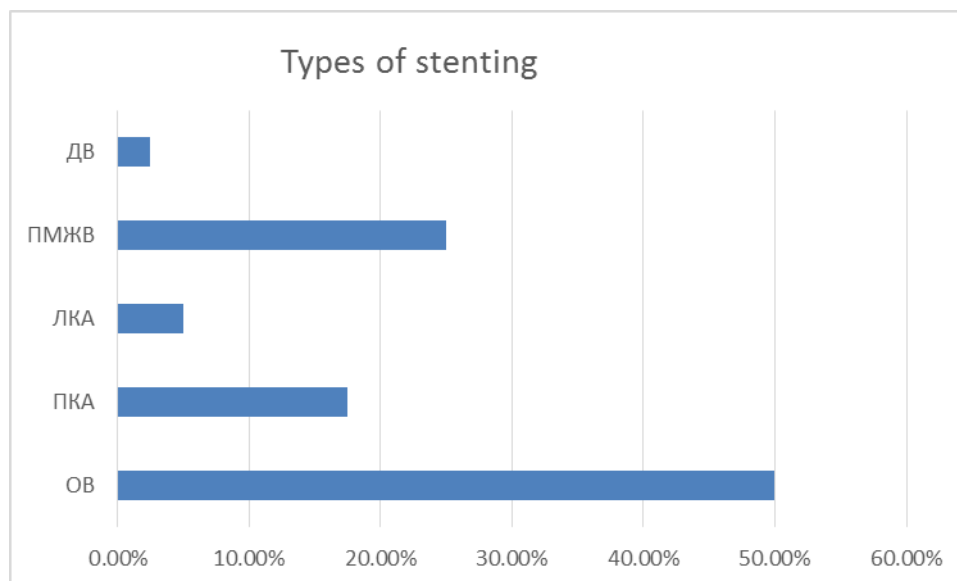
In the course of the study, the right type of blood circulation in 64 patients was 80%, the balanced type in 9 - 11.25% and the left type of blood circulation in 5 - 6.25%. The indication for endovascular intervention (EV) was the presence of acute coronary syndrome, as well as angiographic presence of coronary artery stenosis of more than 70%. Patients during coronary angiography were determined by the degree of damage to the branches of the coronary vessels, as well as their localization. Damage to the branches of the coronary vessels are presented in diagram 2.

**Diagram №2 Damage to the branches of the coronary vessels**



Stenting of the circumflex branch (OB) - 40 (50.0%), stenting of the right coronary artery (RCA) - 14 (17.5%), stenting of the left coronary artery (LCA) - 4 (5%), stenting of the anterior interventricular branch (LAD) - 20 (25%), stenting of the diagonal branch (DV) - 2 (2.5%) patients. A clinically good result after the procedure was considered to be the absence of angina pectoris and an increase in exercise tolerance. Types of stenting are presented in diagram #3.

Diagram № 3 Types of stenting



During coronary stenting, all patients received a Resoluty integrity drug-eluting stent with different diameters and pressures depending on the degree of vascular damage.

All patients after PCI were prescribed dual anticoagulant therapy - acetylsalicylic acid and clopidogrel, enoxaparin, and after discharge (rivaroxaban) and rosuvastatin (mertenil, Gedeon Richter).

During the study, a blood test was taken from all patients for the level of NT-proBNP and an echocardiogram was performed with the determination of LVSD and E / e' which are predictors of early chronic insufficiency. During the study, in patients with PICS and subacute MI, the level of NT-proBNP significantly increased, compared with patients with unstable angina (Table No. 1).

Our study showed that more vessels treated were independently associated with greater improvement in LVEF (5.5% improvement in LVEF with 1-vessel treatment, 6.6% with 2-vessel treatment, 8.3% with 3 vessels, by 11.2% in the treatment of 4 vessels).

**Dynamics indicators diastolic functions in comparison with concentration natriuretic peptide.**

Table 1.

Indicators	Patients with PICS and subacute MI (n=66)					
	Initially	After stenting	R (1-2)	6 months	P(1-3)*	Δ(1-3)**
SDLA,mm rt.st.	51.25 (45.78-58.72)	47.32 (41.49-55.15)	0.060	47.39 (40.04-56.74)	0.061	-3.17 (-8.54-2.21)
Volume LP,ml	127.75 (110.09-147.41)	126.37 (107.36-145.37)	0.266	126.56 (100.77-154.35)	0.965	-0.21
E/E'	22.20 (18.44-26.04)	25.50 (20.35-30.81)	0.050	28 (20.73-27.27)	0.210	-3.00 (-6.86-0.8)
NTproBNP	2700.4 (3911.7-9649.1)	4460.18 (2097.81-6842.54)	0.009	8330.61 (1279.34-3401.88)	0.002	-3057
Indicators	Patients with unstable angina (n=14)					
	Initially	Standard Therapy	R(1-2)	6 months	P(1-3)*	Δ(1-3)**
SDLA,mm rt.st.	46.19 (40.03-54.35)	46.45 (38.3-54.6)	0.917	46.89 (36.37-57.41)	0.505	1.89 (-3.96-7.74)

Volume LP,ml	120.86 (101.46-140.26)	118.32 (98.65-137.99)	0.568	123.17 (101.65-144.68)	0.178	3.67
E/E'	27.28 (23.45-31.1)	27.28 (23.45-31.1)	0.237	23.56 (20.02-27.1)	0.296	1.57 (-1.5-4.65)
NTproBNP	5315.62 (2425.618207.63)	3741.69 (1712.67-5770.72)	0.016	2203.92 (1117.06-3290.78)	0.002	-1554.96

*\*Significance of differences between baseline and 6 months*

*\*\* Change in parameter between baseline and values after 6 months observed*

In our study, all patients underwent only coronary artery stenting; coronary artery bypass grafting was not taken into account. There were no lethal cases and serious complications during the intervention and after it during the stay in the hospital.

**Results.** The study found that in elderly people with a diagnosis of coronary artery disease: postinfarction cardiosclerosis (PICS) - 40% (n=32), with myocardial infarction 42.5% (n=34), angina pectoris FC 3 17.5% (n=14). From diagram No. 2, it can be seen that the circumflex branch is most affected in 40 patients, the average level of damage was 80%, the anterior interventricular branch (LAB) - 20 (25%), in which the average level of damage is 70%, 14 patients are affected by the right coronary artery (RCA), which amounted to 70% of the average level, in 49 patients the obtuse marginal branch (OBB) was affected, which amounted to 69%, the diagonal branch (DV) was affected in 2 patients and amounted to 78%, who underwent stenting of the coronary arteries there is a significant increase in LV EF, E/e'e and the levelNTproBNP.

It is necessary to study the comparative long-term follow-up of patients diagnosed with postinfarction cardiosclerosis in the elderly - 32 patients (40.0%), patients with acute myocardial infarction underwent stenting in 14 patients, which amounted to 8.6%. Various types of stenting were also involved - recanalization of an occluded coronary artery in 30.67% of patients, balloon angioplasty in 42.33% of patients, in other patients stenting of various sections of the coronary arteries. All patients before and after PCI were prescribed statins, in particular, rosuvastatin - mertenil at a dose of 20 mg/day, double or triple anticoagulant therapy - acetylsalicylic acid and clopidogrel, or enoxaparin (rivaroxaban).

After stenting, the patients were in the hospital under observation and no angina pectoris attacks were observed in patients before discharge from the hospital.

**Discussion.** Comparative long-term follow-up of elderly patients is to be studied. The importance of stenting in elderly patients with CIHD, who have a high level of comorbidity, is likely to be quite high, while the need for stenting in patients who have had myocardial infarction with postinfarction cardiosclerosis raises many questions. It is necessary to study the presence of early chronic heart failure in these patients to address the issue of the need for coronary artery stenting and improve the quality of life.

**Findings:** Currently, interventional surgery, which includes coronary artery stenting, balloon angioplasty and coronary artery bypass grafting, are at the peak of treatment for patients with coronary heart disease. However, a more careful selection of comorbid patients should be carried out taking into account age, patients with complicated chronic heart failure, for whom it is important to study the level of brain natriuretic peptide, as well as long-term monitoring of the outcomes of surgical intervention.

#### Literature:

1. Adams KF Jr., Fonarow GC, Emerman CL, et al. Characteristics and outcomes of patients hospitalized for heart failure in the United States: rationale, design, and preliminary observations from the first 100,000 cases in the Acute Decompensated Heart Failure National Registry (ADHERE). *Am Heart J* 2005;149:209–16

2. Agababyan, IR, & AA, R. (2019). The diagnostic value of routine research methods electrocardiography and echocardiography in patients with chronic heart failure elderly. In International Conference "Process Management and Scientific Developments" (pp. 168-171).
3. Agababyan, I., Yarasheva, Z., Nasretdinova, M. The Importance of Echocardiography in the Detection of Early Chronic Heart Failure in Elderly Patients *Kardiologija v Belarusi* this link is disabled, 2022, 14(3), pp. 313–318
4. Gheorghide M, Bonow R.O. Chronic heart failure in the United States: a manifestation of coronary artery disease. *Circulation* 1998;97:282–9.
5. Passamani E, Davis KB, Gillespie MJ, Killip T. A randomized trial of coronary artery bypass surgery. Survival of patients with a low ejection fraction. *N Engl J Med* 1985;312:1665–71.
6. Velazquez EJ, Lee KL, Deja MA, et al. Coronary artery bypass surgery in patients with left ventricular dysfunction. *N Engl J Med* 2011;364: 1607–16.
7. Daubert MA, Massaro J, Liao L, et al. High-risk percutaneous coronary intervention is associated with reverse left ventricular remodeling and improved outcomes in patients with coronary artery disease and reduced ejection fraction. *Am Heart J* 2015;170:550–8.
8. Lewis GF, Harless AC, Vazquez L, et al. Natural history and implantable cardioverter-defibrillator implantation after revascularization for stable coronary artery disease with depressed ejection fraction. *Clin Cardiol* 2015;38:715–9.
9. Russo JJ, Prasad M, Doshi D, et al. Improvement in left ventricular function following higher-risk percutaneous coronary intervention in patients with ischemic cardiomyopathy. *Catheter Cardiovasc Interv* 2020;96: 764–70.
10. Hao K, Takahashi J, Sakata Y, et al. Prognostic impact of residual stenosis after percutaneous coronary intervention in patients with ischemic heart failure—a report from the CHART–2 study. *Int J Cardiol* 2019;278:22–7.
11. Yarasheva Z. H. Echocardiographic significance in the detection of early chronic heart failure in elderly patients who underwent percutaneous coronary intervention // *BARQARORLIK VA YETAKCHI TADQIQOTLAR ONLAYN ILMIIY JURNALI*. – 2022. – pp. 124-128.